

## Review Article

# Hyperparathyroidism-jaw tumor syndrome: A rare disorder with significant clinical features

Dimitrios Kourkoulotis

*Postgraduate Program Metabolic Bone Diseases, School of Medicine, National and Kapodistrian University of Athens, Greece***Abstract**

Hyperparathyroidism-jaw tumor syndrome is a rare disorder that is inherited in an autosomal dominant manner and predisposes to the development of parathyroid adenomas and carcinoma, ossifying jaw tumors, uterine neoplasms and renal cysts. It is caused by inactivating mutations in the gene CDC73 that it was first identified in 2002. The purpose of this narrative review is to highlight the genetic background of the syndrome and its clinical manifestations as well as to emphasize the significance of genetic testing in diagnosis from an early age. The clinical and familial features of the syndrome were collected by searching on electronic database PubMed/Medline using the MeSH terms “Hyperparathyroidism-jaw tumor syndrome” or “HPT-JT syndrome”. 246 articles were returned of which, 44 were reviews and 59 case reports. Two nationwide retrospective studies were found. This article is focused mainly on data from the last decade, as there seems to be a better understanding of the genetic basis due to the evolution of DNA sequencing techniques. To date, there have been over 200 patients reported in approximately 50 families carrying a germline mutation of CDC73 gene, suggesting that there should be an augmented awareness of identifying both patients and their relatives.

**Keywords:** CDC73 gene, Genetic testing, Hyperparathyroidism-jaw tumor syndrome, Jaw tumors, Parathyroid carcinoma

**Introduction**

Primary hyperparathyroidism (pHPT) is one of the most common endocrine disorders and is characterized by excessive and irregular secretion of parathyroid hormone (PTH), resulting in hypercalcemia<sup>1,2</sup>. In 80-85% of cases this is due to the presence of benign adenoma in a single parathyroid gland, whilst in 10-15% it may be due to multiglandular tumors or hyperplasia and parathyroid malignancy (<1%)<sup>2,3</sup>. It is usually revealed during the sixth decade of life affecting mainly women, in a ratio 2-3:1 female to male, whilst the prevalence in the population is 1-4 per 1000 persons<sup>4,5</sup>. Although the vast majority of cases arise sporadically, pHPT may be the manifestation of some genetic inherited syndromes, in a notable percentage of 5-10%<sup>5,6</sup>. One such disorder is hyperparathyroidism jaw tumor syndrome (HPT-JT).

This syndrome is inherited in an autosomal dominant manner and is characterized by the development of parathyroid tumors causing pHPT, ossifying fibromas of the jaws, as well as the upgrowth of uterine neoplasms and renal cystic lesions<sup>7,8</sup>. It is caused by inactivating mutations in the tumor suppressor gene CDC73 (cell division cycle 73)

that is located in chromosome 1 and, more specifically, in position 1q31.2<sup>9</sup>. CDC73 gene encodes for a ubiquitously expressed nuclear protein with strong anti-proliferative properties called parafibromin (from hyperPARA and FIBRO-osseous)<sup>10</sup>. Mutations or deletions occurring in this gene lead to loss of parafibromin’s functionality resulting in the development of a variety of human neoplasms in patients suffering from the syndrome<sup>11</sup>.

Newer data suggest that there might be a strong correlation between CDC73 gene mutations and the development of parathyroid cancer (PC) and jaw tumors<sup>12</sup>. Recent advances in the understanding of the genetic basis

*The author has no conflict of interest.*

**Corresponding author:** Dimitrios Kourkoulotis, Mikras Asias 75, 11527, Athens, Greece

**E-mail:** dim.kourkoulotis@gmail.com

**Edited by:** Konstantinos Stathopoulos

**Accepted** 20 February 2023

have shown that somatic only CDC73 mutations could lead to PC, indicating that there is a high life risk of malignancy in the setting of HPT-JT syndrome<sup>13</sup>. Early identification of both patients and relatives harboring CDC73 mutations is crucial so as to assure a better clinical outcome of them<sup>14,15</sup>.

## Genetic background

### CDC73 gene

HPT-JT syndrome is caused by inactivating mutations in the tumor suppressor gene CDC73 that is located in the long arm of chromosome 1 and, more specifically, in position 1q31.2<sup>7,8</sup>. It was first identified by Carpten in 2002, who designated it as a HRPT2 (hyperparathyroidism tumor 2) gene, and consists of 17 exons and a coding area of 1593 bases<sup>8,16,17</sup>. CDC73 gene encodes for an evolutionary conserved protein, known as parafibromin<sup>8,12</sup>. This protein consists of 531 amino acids, is predominantly expressed in the nucleus of the cells and can be found in many tissues of the human body such as parathyroid and adrenal glands, kidneys, heart, hypophysis and skeletal muscles<sup>8,18,19</sup>. Parafibromin shows off strong anti-proliferative properties and is a component of Polymerase-Associated Factor 1 complex (PAF1c) that includes, overall, five more proteins<sup>17,20</sup>. Via this complex, parafibromin interacts directly with RNA-polymerase II impacting significant transcriptional and post-transcriptional procedures such as histones modification, stabilization of p53, mRNA elongation and chromatin remodeling<sup>8-10,15,20</sup>. Also, it is suggested by many recent studies that parafibromin downregulates both Cyclin D1 and c-Myc proto-oncogene expression, resulting in the inhibition of the cell cycle progression and further, interacts directly with  $\beta$ -catenin in the nucleus, activating the canonical Wnt signaling pathway<sup>8,13,15,17,20-22</sup>. Moreover, it seems to play an important role in embryogenic development and organogenesis<sup>20,21</sup>. Germline mutations or deletions occurring in the CDC73 gene lead to premature truncation of parafibromin and subsequent loss of its properties, inducing the growth of a variety of human neoplasms<sup>8,11,22</sup>.

### Mutations

Germline and somatic mutations occurring in CDC73 gene seem to be associated with pathogenic phenotypes of HPT-JT syndrome, familiar isolated hyperparathyroidism (FIH) and sporadic PC<sup>4,7,23-25</sup>. Indeed, from the patients harboring a CDC73 mutation, 55% have manifestations related to HPT-JT syndrome, 21% to FIH, whilst a percentage of 15-20% appears to develop PC<sup>9,20,23,24</sup>. In regards to the patients with HPT-JT syndrome, 50-75% are carriers of germline mutations, whereas the remaining 25% might present abnormalities in the promoter region, whole exon deletions, mutations in unidentified genes, epigenetic modifications or methylation leading to gene silencing<sup>8,9,20,23,26</sup>.

The vast majority of germline mutations is related to frameshift and nonsense ones, which are detected in 50-60% and 30% of the syndromic probands, respectively,

whilst missense and splice-siting mutations are found more rarely (5-13%)<sup>9,20</sup>. Strikingly, 65-80% of these mutations are predominantly located in exons 1, 2 and 7, howbeit they can be scattered out along the whole coding area<sup>9,16,18,20</sup>. Also, as it has been shown by numerous studies, in 1/3 of the cases a gross deletion of whole exons, that might even expand beyond CDC73 gene, is observed, yet without being necessarily linked to more severe clinical features<sup>11,23,27-32</sup>.

It is suggested that over 80% of these mutations induce premature truncation of parafibromin by creating a stop codon, resulting in functional loss of the protein<sup>8,11,27,33</sup>. In fact, Wei Sun et al point out that most pathogenic mutations, especially the missense ones, disrupt the folding or thermostability of N-Terminal Domain (NTD) of CDC73, leading to a short non-functional protein<sup>21</sup>.

However, as Li et al assert in a very recent cohort study, not all mutations draw the same impact on the functionality of parafibromin but instead, they can be distinguished into "high and low impact" mutations<sup>12</sup>. Indeed, it has been underscored by several studies and reviews that mutations causing gross disruption of parafibromin's structure (frameshift, nonsense, deletions) are more likely to be associated with classical features of HPT-JT syndrome and development of PC, whereas more rare mutations (missense) are linked to other pHPT syndromes without typical features (FIH)<sup>5,7,8,12,15,23,25</sup>.

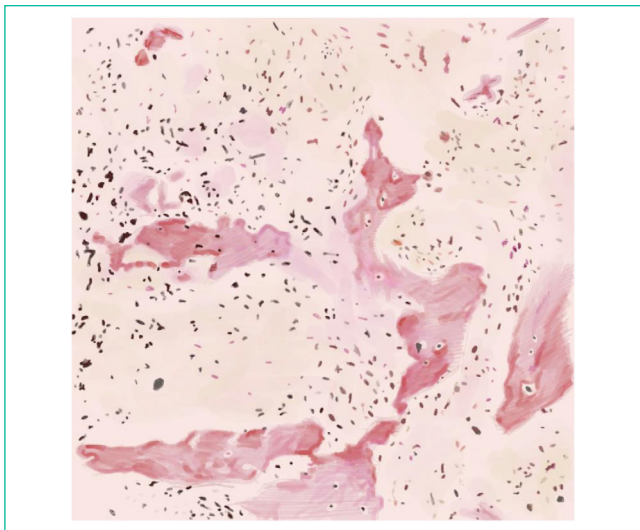### Penetrance-expressivity

All research advocates that the penetrance of the syndrome is incomplete and it usually ranges from 70% to 95%<sup>7,8,25,29,30,34</sup>. That means approximately 10-30% of the probands bearing a CDC73 germline mutation will lack any clinical feature related to the syndrome<sup>5,9,18,33</sup>. Recent cohort studies in affected families demonstrated that penetrance seems to increase with age and, more specifically, it is formulated as follows: 25-30 years old: 15%, 40-50 years old: 60%, 70 years old: 85%<sup>4,25</sup>. Intriguingly, for reasons unknown, it appears to be slightly more increased in females<sup>17</sup>.

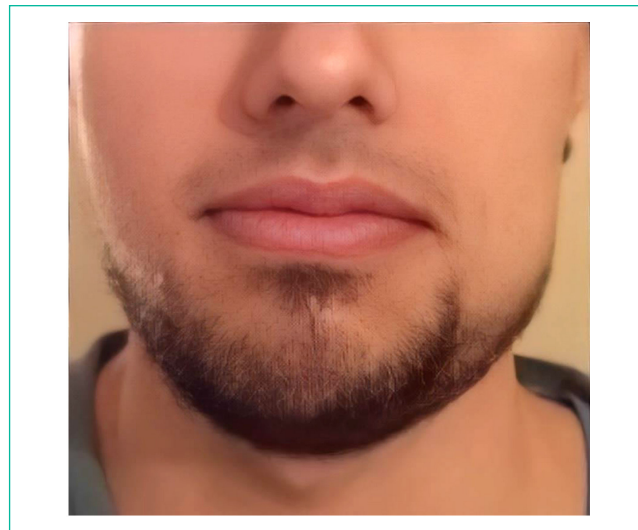
Expressivity of the syndrome is variable and, to date, an unequivocal phenotype-genotype correlation has not been established<sup>4,7,8,18,23-25</sup>. A prominent example is the case currently described by Le Collen et al, where two monozygotic twins manifested a completely contrasting expression, with the first suffering from acute hypercalcemia and renal failure, whilst the second presented almost normal serum calcium levels<sup>25</sup>.

### Knudson two-hit hypothesis

As it has already been mentioned, CDC73 is a tumor suppressor gene and HPT-JT syndrome ensues from germline mutations in it<sup>7</sup>. Consistent with Knudson two-hit hypothesis, biallelic inactivation is entailed for tumorigenesis. Indeed, it seems that the first germline mutation achieves a predisposition to the neoplastic progression, whilst a



**Figure 1.** Histological image of ossifying fibroma of the jaws. Area of cellular fibrous tissue with focal deposits of newly formed abnormal bone-like material.



**Figure 2.** Clinical presentation of ossifying fibroma in the left posterior mandible in a young male. Expansion of the buccal plate leading to facial asymmetry.

subsequent second hit, that affects the normal allele and leads to loss of heterozygosity, is necessary for the ultimate tumors' development<sup>5,7-9,23,25,28,34,35</sup>.

## Clinical features

### Primary hyperparathyroidism

Hyperparathyroidism is the salient manifestation of the syndrome and is found in 80-100% of the affected probands<sup>1,4,7,8,25,29,33,36</sup>. At variance with the other inherited forms of pHPT that are due to multiglandular involvement, a single gland parathyroid adenoma is detected in 80-95% of the syndromic patients<sup>8,9,25,29,35</sup>. Histologically, parathyroid adenomas related to the syndrome tend to show microcystic changes<sup>16</sup>. Multiple synchronous parathyroid tumors, in contrast to what was previously believed, are more rarely observed with the percentage ranging from 13% to 30%, even though it has been underscored that the majority of the patients will ultimately develop multiglandular disease, in the long term<sup>8,16,25,29,35</sup>. Hyperparathyroidism might, also, be the symptom of PC in a meaningful percentage (15-23%) of patients with the syndrome<sup>5,15,25</sup>.

Notwithstanding the fact that pHPT typically affects people of the 5<sup>th</sup>-6<sup>th</sup> decade of life, in HPT-JT syndrome it is usually revealed in late adolescence or early adulthood with a median age of diagnosis in 32 years<sup>2,4,6,8,26,33</sup>. Of course, from studies conducted in families with the syndrome, there is a variation in the age of onset between 13 and 38 years, whilst the earliest age reported is 7 years<sup>4,10,16,18,23,25,35,37</sup>. Notably, it appears to occur with the same frequency in both sexes and not predominantly in females, as is the case in

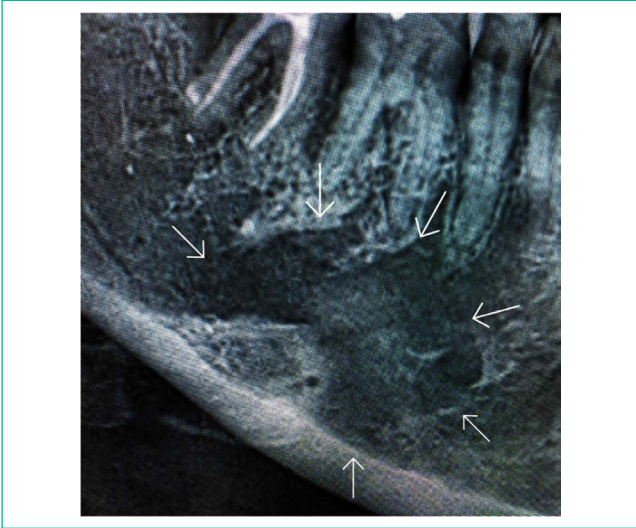sporadic cases<sup>23</sup>.

pHPT in HPT-JT syndrome is usually mild and appears as a prolonged moderate hypercalcemia, that might even go unnoticed, with the total serum calcium levels ranging below or equal to 12 mg/dL<sup>7,8,14,29,32</sup>. However, in case of multiglandular involvement, calcium levels might exceed the limit of 12 mg/dL, whilst, in presence of PC, a severe hypercalcemic crisis with nausea, vomiting, fatigue and bone pain can be observed<sup>15,23,30,35,38</sup>. Mehta et al, typically, report a shooting in calcium levels to 13,1 mg/dL in patients with PC compared to those with benign parathyroid disease (11,7 mg/dL)<sup>29</sup>. In a recent cohort study, Le Collen et al accentuate that the intensity of HPT is unpredictable, as they observed in patients with HPT-JT syndrome and single gland involvement a rapid deterioration of calcium levels above 12 mg/dL (12,5±2,8 mg/dL)<sup>25</sup>.

Finally, in about 25% of patients that underwent selective parathyroidectomy for benign parathyroid adenoma, a metachronous recurrent pHPT might be observed, years after being disease-free, due to a novel single-gland parathyroid neoplasm<sup>8,14,16,37,38</sup>.

### Jaw tumors

In spite of the denomination of the syndrome, jaw tumors are found in approximately 30-40% of the affected patients<sup>7,14,19</sup>. These are called ossifying fibromas and, by definition, are benign, slow growing masses that histologically consist of avascular fibroblastic stroma with spindled neoplastic cells that produce various amounts of aberrant mineralized and cementum-like material (Figure 1)<sup>19,22</sup>. In



**Figure 3.** Radiographic image of ossifying fibroma in the right posterior area of the mandible. A well-demarcated unilateral lucent lesion (white arrows) without destructive features or root resorption can be seen in the area of molars-premolars.

contrast to the sporadic variants that are usually revealed after the 4<sup>th</sup> decade of life, ossifying fibromas related to the syndrome have an average onset age of 30 years<sup>19,26,39</sup>. In fact, the earliest age reported is 10 years<sup>19</sup>. CDC73 gene mutations are rarely found in sporadic fibromas and seem to play a minor role in their initiation, whereas the vast majority of syndromic-related jaw tumors (80%) is positive for genetic mutations<sup>19,26,40</sup>. Li et al, interestingly, highlight that probands harboring a high-impact germline mutation present a higher risk of developing ossifying fibromas than those with low-impact mutations<sup>12</sup>.

Clinically, ossifying fibromas might cause a firm, hard swelling of the buccal and lingual bones of the mandible or maxilla leading to apparent facial asymmetry and deformity, whilst, in other cases, an indolent bone tumefaction might be faintly observed (Figure 2)<sup>3,11,26,39</sup>. Given the fact that ossifying fibromas demonstrate a strong tendency to keep enlarging (>10 cm), if left untreated, in addition to cosmetic issues, they can lead to dentition disruption, breathing difficulties, pain and paresthesia to teeth and lips due to pressure to adjacent structures such as the inferior alveolar nerve<sup>8,14,26</sup>. Radiologically, these tumors are usually presented as well-circumscribed radiolucent lesions with a sclerotic rim opposed to sporadic variants that are commonly displaying a mixed (radiolucent/opaque) appearance (Figure 3)<sup>8,11,39,40</sup>. Additionally, they can be bilateral and/or multifocal<sup>8,26</sup>.

In terms of origin, they seem to derive from the mesenchymal blast cells of the periodontal ligament and this is amplified by the fact that fibromas related to the syndrome are confined exclusively to the areas of molars and

premolars and never appear in the angle or ascending ramus of the mandible (where no teeth are bearing)<sup>5,19</sup>. Mandible is affected in an overwhelming percentage of 70%, maxilla in 20% and both in 10% of observed cases<sup>19</sup>. It is of utmost importance to emphasize that jaw tumors, in about 25% of cases, may precede the manifestation of HPT. On one hand, this indicates the genetically independent development of these two symptoms, but on the other, raises the attention of clinical practitioners for misleading the diagnosis<sup>19,26</sup>.

Finally, complete treatment is only achieved through surgical resection of the tumors or through encapsulation for smaller lesions<sup>11</sup>. Differential diagnosis from brown tumors is based on the fact that ossifying fibromas do not resolve after correction of hyperparathyroidism<sup>5,7,19,26</sup>. Notwithstanding the almost zero possibility of malignant degeneration (<0,5%), a long-term follow up is strongly recommended, given the risk of recurrence especially in younger patients<sup>14,26,39</sup>.

### Parathyroid carcinoma

Patients with HPT-JT syndrome appear to have an increased lifetime risk of developing PC, compared to other inherited forms of pHPT, with the probability ranging from 15% to 20%<sup>4,8,23,24,36</sup>. Should we take into account that PC is the cause of less than 1% of all cases of pHPT, then the existence of a strong association can be reasonably hypothesized between these disorders<sup>15</sup>. Indeed, studies have shown that up to 70% of sporadic PCs harbor a somatic mutation in CDC73 gene, whilst in 1/3 of cases, germline mutations are revealed<sup>16,28,41,42</sup>. This, strikingly, means 20-30% of patients with sporadic PC bear a germline mutation and, hence, there is a severe chance of suffering from undiagnosed HPT-JT syndrome<sup>15,16,20,28,37,41,42</sup>.

For these reasons, according to the most recent directions from the World Health Organization (WHO), it is strongly recommended that all individuals with PC and their relatives, should be offered genetic screening for mutations in CDC73 gene<sup>13,36,37</sup>. In addition, newer data suggest that probands carrying frameshift or nonsense mutations are seven-times more likely to develop PC than those carrying missense ones, but without an unequivocal phenotype-genotype correlation having been established<sup>5,12</sup>.

There are no specific clinical criteria for diagnosis of PC as it is usually confirmed histologically after surgery, but compared to benign tumors, there are some features raising suspicion:

- Persistent hypercalcemia with total serum Ca<sup>2+</sup> >12 mg/dL (>3 mmol/L).
- Markedly elevated PTH levels 3-10 times above normal limit.
- Parathyroid lesion greater than 3 cm.
- Palpable cervical mass.
- Concomitant general symptoms (cachexia, weakness, fatigue), renal lesions (nephrolithiasis) and skeletal manifestations (bone pain)<sup>14,15,20,41,42</sup>.

Of course, clinical doctors should also keep in mind the very scarce cases of non-functional PCs (<2%) as well as atypical adenomas, which are able to induce similar symptomatology<sup>15,41</sup>. The youngest syndromic patient reported for developing PC is 8 years old and thus, genetic testing from an early age (<10 y.o.) should be considered<sup>1</sup>.

In patients with HPT-JT syndrome that have undergone surgery (en bloc resection) for PC, a long term follow up is indispensable, as recurrence has been observed in 66% of these patients, over a period of 16 years (variation >50%)<sup>15,38,42,43</sup>.

### **Uterine tumors**

Neoplastic uterine lesions are the second most common manifestation of HPT-JT syndrome and are found in 50-75% of the affected women<sup>8,14,18,23,33,44</sup>. A range of uterine pathology has been reported including benign tumors such as adenofibromas, leiomyomas, adenomyomatous polyps, as well as endometrial hyperplasia and adenomyosis<sup>8,9,14,16,30,45,46</sup>. Adenosarcomas have also been observed in a subset of adult female carriers<sup>8,23,45</sup>. Interestingly, these lesions seem to share a common embryologic origin with the Mullerian duct system<sup>7,8,35,45,46</sup>. In addition to uterine neoplasms, affected women appear to undergo hysterectomy from an early age (<35 y.o.) due to persistent menorrhagia, whilst multiple miscarriages and an impaired ability to bear children, compared to unaffected female siblings, are frequently described<sup>5,14,45</sup>.

Despite the fact that there are no guidelines for regular gynecological screening for those carrying a CDC73 germline mutation, a lifelong monitoring with routine care and pelvic ultrasound, starting from reproductive age, is strongly recommended. This aims to not only achieve a reduction to morbidity and mortality but also increase the chances of the affected women to bear children<sup>5,8,46</sup>.

### **Renal lesions**

Renal manifestations related to HPT-JT syndrome are more rarely described and are found in 15-20% of the affected probands<sup>11,18,23,25,35</sup>. The presence of multiple renal cysts leading to polycystic disease seems to be the most common feature of renal involvement<sup>8,14,16</sup>. A variety of kidney tumors has also been reported including hamartomas, Wilms tumors, renal cell carcinoma, mixed epithelial and stromal tumors (MEST)<sup>7,9,16,33,44</sup>. In regards to the latter, notwithstanding the fact that they are poorly reported, it is suggested that they might be associated with a specific CDC73 missense mutation implying a potential phenotype-genotype correlation<sup>5,47</sup>. Given the chance of MEST to undergo malignant transformation, the early identification and management of HPT-JT syndromic patients with renal involvement is of utmost importance<sup>47</sup>.

Lastly, taking into consideration that the affected probands are at a lifetime risk of developing multiple bilateral kidney lesions, a nephron-sparing surgery rather than a radical one should be opted for, so as to preserve renal function<sup>8,47</sup>.

### **Other associated features**

A variety of other human neoplasms have also been described in patients with HPT-JT syndrome, howbeit it remains unclear whether they are at higher risk of developing these tumors compared to the general population<sup>7,8</sup>. Pancreatic adenocarcinoma, testicular germ cell tumors, thyroid papillary carcinoma, colon cancer, cholangiocarcinoma, chronic lymphatic leukemia and pituitary cysts are some uncommon neoplasms that have been observed in HPT-JT syndrome<sup>7,8,14,16,25,35</sup>.

Furthermore, it has been underscored that gross deletions expanding beyond the 1q25-32 region, where the CDC73 gene is located at and, hence, affect other genes, may be associated with development delay syndromes in children. However, these observations have been made in only two case reports so far and, thus, more research is required in order to elucidate whether there is a true association between development delay and children bearing a CDC73 gene deletion<sup>31,32</sup>.

## **Diagnosis**

### **Genetic test**

Diagnosis can be achieved only via genetic screening for mutations in CDC73 gene and this remains the gold standard for corroborating the existence of HPT-JT syndrome<sup>8,14</sup>. According to the last consensus of the European society of Endocrine Surgeons (ESES) the following indications should raise the suspicion of the clinical doctor and should prompt genetic testing:

- Patients with sporadic pHPT and age <35-40 years old.
- Patients who have at least one first or second degree relative with familial pHPT, after exclusion of MEN1 syndrome.
- Ossifying fibromas of the jaws, uterine tumors and renal lesions, with or without coexistence of hyperparathyroidism.
- Histological findings of cystic or atypical changes of parathyroid adenomas or diagnosis of PC.
- Parathyroid tumors negative for parafibromin immunohistochemical (IHC) staining.
- Multiglandular disease and persistent recurrence of pHPT<sup>2,4,7,8,15,25,32</sup>.

It has been suggested that genetic testing should start before the age of ten, as the youngest patient reported with HPT-JT syndrome, so far, is 7 years old<sup>8,9,25,29</sup>. It is important to stress that if direct DNA sequencing for point mutations is negative in an individual suspicious for CDC73 germline mutations, the deployment of more advanced techniques (qPCR) for detection of whole gene deletion is crucial<sup>23,24,27,28,32</sup>.

Benefits of genetic analysis are multiple as it provides the opportunity of early diagnosis and facilitates the management of subsequent manifestations associated with HPT-JT syndrome. Also, it promotes the enrolment of relatives in a long-term follow-up regime leading to early identification of family members at risk<sup>6,18</sup>. Should we take

into account that, according to Newey et al, first degree relatives have 50% chance of developing HPT-JT syndrome-related tumors, then, we can easily conclude that early genetic screening is of paramount importance<sup>9</sup>.

### Parafibromin IHC staining

Absence of nuclear parafibromin expression via IHC staining, has been proposed as a cost-effective diagnostic tool for indirectly recognizing patients with HPT-JT syndrome<sup>7,8,29</sup>. “Parafibromin deficient parathyroid neoplasms” is a newly inserted term that, according to 2022 WHO classification, refers to parathyroid tumors with complete absence of nuclear parafibromin immunoreactivity<sup>13</sup>. In fact, these neoplasms demonstrate distinctive morphologic features such as eosinophilic cells, a sheet-like rather than acinar growth pattern, a thick capsule and vascular space invasion<sup>13,37</sup>. Negative nuclear parafibromin staining is associated with underlying CDC73 biallelic inactivation and, therefore, should raise the suspicion for HPT-JT syndrome, leading to further molecular testing<sup>13,29,37</sup>. On the other hand, cytoplasm expression has no relation with the mutational status and overexpression in it could mask the loss of nuclear expression<sup>10</sup>.

It is suggested that high impact mutations ensue diffuse loss of parafibromin nuclear expression, whilst some low impact mutations can result in preserved parafibromin expression, yet causing pathological phenotypes. Therefore, despite the fact that IHC method could lead to missed diagnosis of a small proportion of low impact mutations, positive IHC staining should not exclude the possibility of an underlying CDC73 inactivation<sup>10,12,13</sup>.

### Surveillance

Patients that have been diagnosed with HPT-JT syndrome via genetic screening, should be deliberately subjected to a regular, life-long monitoring regime<sup>25</sup>. Given the risk of developing a variety of human neoplasms, the high recurrence rates of pHPT (25%) and, even, the lofty likelihood of parathyroid malignancy (20%) metachronously<sup>8,15,35</sup>, a surveillance program should include the following:

- Evaluation of serum calcium levels, PTH, vitamin D and creatinine every 6-12 months.
- Occasional ultrasound examination of the parathyroid glands.
- Dental imaging with panoramic X-ray at least every 5 years.
- Renal ultrasound examination or magnetic resonance imaging every 5 years.
- Regular gynecologic care with pelvic ultrasound examination, starting from reproductive age<sup>7,8,14,29,32</sup>.

### Discussion

HPT-JT syndrome is a rare genetic disorder belonging to the inherited forms of pHPT and is characterized by the development of neoplastic lesions in tissues other

than parathyroid glands. Ossifying fibromas of the jaws, uterine tumors and renal cystic lesions are manifestations that may appear concomitantly with the main symptom of hyperparathyroidism and may, even, create a differential diagnostic issue in the clinician. Additionally, more and more recent research has indicated the potential association of parathyroid malignancy with somatic and germline mutations in CDC73 gene, suggesting a higher risk of syndromic probands developing PC, compared to the other inherited forms of pHPT. This lifetime risk reaches 20%.

Therefore, despite the scarcity of HPT-JT syndrome, knowledge of the genetic background and its clinical manifestations is crucial, as it highlights a significant tool in the quiver of clinical doctors; genetic screening. Through screening, early diagnosis and identification of both patients and their relatives that may harbor mutations in CDC73 gene is rendered feasible. Furthermore, genetic testing from an early age (<10 y.o.) facilitates the management of syndrome-related neoplasms and promotes the enrolment of carriers, especially the young ones, in a long-term follow-up regime. Prevention of PC, timely surgical treatment of jaw tumors, reduction of morbidity due to uterine tumors and maintenance of renal function should be the primary purposes in the management of families suffering from HPT-JT syndrome.

Lastly, after appropriate surgical treatment of parathyroid tumors, the subsumption of patients in a lifelong surveillance program should be considered essential, as recurrence of hyperparathyroidism due to metachronous parathyroid tumors has been observed in up to 25% of the operated probands.

### References

1. Cristina EV, Alberto F. Management of familial hyperparathyroidism syndromes: MEN1, MEN2, MEN4, HPT-Jaw tumour, Familial isolated hyperparathyroidism, FHH, and neonatal severe hyperparathyroidism. *Best Pract Res Clin Endocrinol Metab* 2018;32(6):861–75.
2. Masi L. Primary Hyperparathyroidism. *Front Horm Res* 2019;51:1–12.
3. Ennazk L, El Mghari G, El Ansari N. Jaw tumor in primary hyperparathyroidism is not always a brown tumor. Vol. 13, *Clinical cases in mineral and bone metabolism: the official journal of the Italian Society of Osteoporosis, Mineral Metabolism, and Skeletal Diseases* 2016. p. 64–6.
4. van der Tuin K, Tops CMJ, Adank MA, Cobben JM, Hamdy NAT, Jongmans MC, et al. CDC73-Related Disorders: Clinical Manifestations and Case Detection in Primary Hyperparathyroidism. *J Clin Endocrinol Metab* 2017;102(12):4534–40.
5. Blau JE, Simonds WF. Familial Hyperparathyroidism. *Front Endocrinol (Lausanne)* 2021;12:623667.
6. Khairi S, Osborne J, Jacobs MF, Clines GT, Miller BS, Hughes DT, et al. Outcome of Clinical Genetic Testing in Patients with Features Suggestive for Hereditary Predisposition to PTH-Mediated Hypercalcemia. *Horm Cancer* 2020;11(5–6):250–5.
7. Iacobone M, Carnaille B, Palazzo FF, Vriens M. Hereditary hyperparathyroidism—a consensus report of the European Society of Endocrine Surgeons (ESES). *Langenbeck's Arch Surg* 2015;

- 400(8):867–86.
8. Torresan F, Iacobone M. Clinical Features, Treatment, and Surveillance of Hyperparathyroidism-Jaw Tumor Syndrome: An Up-to-Date and Review of the Literature. *Int J Endocrinol* 2019;2019:1761030.
  9. Newey PJ, Bowl MR, Cranston T, Thakker R V. Cell division cycle protein 73 homolog (CDC73) mutations in the hyperparathyroidism-jaw tumor syndrome (HPT-JT) and parathyroid tumors. *Hum Mutat* 2010;31(3):295–307.
  10. Turchini J, Gill AJ. Hereditary Parathyroid Disease: Sometimes Pathologists Do Not Know What They Are Missing. *Endocr Pathol* 2020;31(3):218–30.
  11. Parfitt J, Harris M, Wright JM, Kalamchi S. Tumor suppressor gene mutation in a patient with a history of hyperparathyroidism-jaw tumor syndrome and healed generalized osteitis fibrosa cystica: a case report and genetic pathophysiology review. *J Oral Maxillofac Surg Off J Am Assoc Oral Maxillofac Surg* 2015;73(1):194.e1-9.
  12. Li Y, Zhang J, Adikaram PR, Welch J, Guan B, Weinstein LS, et al. Genotype of CDC73 germline mutation determines risk of parathyroid cancer. *Endocr Relat Cancer* 2020;27(9):483–94.
  13. Erickson LA, Mete O, Juhlin CC, Perren A, Gill AJ. Overview of 2022 WHO Classification of Parathyroid Tumors. *Endocr Pathol* 2022.
  14. Barnett M, Ahmed F, Mihai R, Rattan A, Humayun MA. The Unforeseen Diagnosis: Hyperparathyroidism-Jaw Tumour Syndrome Case Report and Review of the Literature. Vol. 2021, *Case reports in endocrinology* 2021. p. 5551203.
  15. Cetani F, Pardi E, Marcocci C. Parathyroid Carcinoma. *Front Horm Res* 2019;51:63–76.
  16. DeLellis RA, Mangray S. Heritable forms of primary hyperparathyroidism: a current perspective. *Histopathology* 2018; 72(1):117–32.
  17. Marx SJ, Goltzman D. Evolution of Our Understanding of the Hyperparathyroid Syndromes: A Historical Perspective. *J Bone Miner Res* 2019;34(1):22–37.
  18. Grigorie D, Sucaliuc A, Ciuffi S, Franceschelli F, Marini F, Ioachim D, et al. High Risk Of Parathyroid Carcinoma And Genetic Screening In The First Diagnosed Romanian Family With Hyperparathyroidism-Jaw Tumor Syndrome And A Germline Mutation Of The CDC73 Gene. Vol. 15, *Acta endocrinologica (Bucharest, Romania: 2005)* 2019. p. 398–403.
  19. Ibrahim HM. Ossifying fibroma of the jaw bones in hyperparathyroidism-jaw tumor syndrome: Analysis of 24 cases retrieved from literatures. *J Dent Sci* 2020;15(4).
  20. Cardoso L, Stevenson M, Thakker R V. Molecular genetics of syndromic and non-syndromic forms of parathyroid carcinoma. *Hum Mutat* 2017;38(12):1621–48.
  21. Sun W, Kuang XL, Liu YP, Tian LF, Yan XX, Xu W. Crystal structure of the N-terminal domain of human CDC73 and its implications for the hyperparathyroidism-jaw tumor (HPT-JT) syndrome. *Sci Rep* 2017;7(1):15638.
  22. Costa-Guda J, Pandya C, Strahl M, Taik P, Sebra R, Chen R, et al. Parafibromin Abnormalities in Ossifying Fibroma. *J Endocr Soc* 2021;5(7):bvab087.
  23. Bricaire L, Odou MF, Cardot-Bauters C, Delemer B, North MO, Salenave S, et al. Frequent large germline HRPT2 deletions in a French National cohort of patients with primary hyperparathyroidism. *J Clin Endocrinol Metab* 2013;98(2):E403-8.
  24. Korpi-Hyövälti E, Cranston T, Ryhänen E, Arola J, Aittomäki K, Sane T, et al. CDC73 intragenic deletion in familial primary hyperparathyroidism associated with parathyroid carcinoma. *J Clin Endocrinol Metab* 2014;99(9):3044–8.
  25. Le Collen L, Barraud S, Braconnier A, Coppin L, Zachar D, Boulagnon C, et al. A large extended family with hyperparathyroidism-jaw tumor syndrome due to deletion of the third exon of CDC73: clinical and molecular features. *Endocrine* 2021;73(3):693–701.
  26. Ibrahim HM. Gnathic Bones and Hyperparathyroidism: A Review on the Metabolic Bony Changes Affecting the Mandible and Maxilla in case of Hyperparathyroidism. *Adv Med* 2020;2020:6836123.
  27. Cascón A, Huarde-Mendicoa CV, Javier Leandro-García L, Letón R, Suela J, Santana A, et al. Detection of the first gross CDC73 germline deletion in an HPT-JT syndrome family. *Genes Chromosomes Cancer* 2011;50(11):922–9.
  28. Domingues R, Tomaz RA, Martins C, Nunes C, Bugalho MJ, Cavaco BM. Identification of the first germline HRPT2 whole-gene deletion in a patient with primary hyperparathyroidism. *Clin Endocrinol (Oxf)* 2012;76(1):33–8.
  29. Mehta A, Patel D, Rosenberg A, Boufraqueh M, Ellis RJ, Nilubol N, et al. Hyperparathyroidism-jaw tumor syndrome: Results of operative management. *Surgery* 2014;156(6):1315.
  30. Muscarella LA, Turchetti D, Fontana A, Baorda F, Palumbo O, la Torre A, et al. Large deletion at the CDC73 gene locus and search for predictive markers of the presence of a CDC73 genetic lesion. *Oncotarget* 2018;9(29):20721–33.
  31. Rubinstein JC, Majumdar SK, Laskin W, Lazaga F, Prasad ML, Carling T, et al. Hyperparathyroidism-Jaw Tumor Syndrome Associated With Large-Scale 1q31 Deletion. Vol. 1, *Journal of the Endocrine Society* 2017. p. 926–30.
  32. Bachmeier C, Patel C, Kanowski P, Sangla K. Should all patients with hyperparathyroidism be screened for a CDC73 mutation? *Endocrinol diabetes Metab case reports* 2018;2018.
  33. Bellido V, Larrañaga I, Guimón M, Martínez-Conde R, Equia A, Perez de Nanclares G, et al. A Novel Mutation in a Patient with Hyperparathyroidism-Jaw Tumour Syndrome. *Endocr Pathol* 2016; 27(2):142–6.
  34. Chiofalo MG, Sparaneo A, Chetta M, Franco R, Baorda F, Cinque L, et al. A novel CDC73 gene mutation in an Italian family with hyperparathyroidism-jaw tumour (HPT-JT) syndrome. *Cell Oncol (Dordr)* 2014;37(4):281–8.
  35. Iacobone M, Masi G, Barzon L, Porzionato A, Macchi V, Ciarleglio FA, et al. Hyperparathyroidism-jaw tumor syndrome: a report of three large kindred. *Langenbeck's Arch Surg* 2009;394(5):817–25.
  36. Mamedova E, Mokrysheva N, Vasilyev E, Petrov V, Pigarova E, Kuznetsov S, et al. Primary hyperparathyroidism in young patients in Russia: high frequency of hyperparathyroidism-jaw tumor syndrome. *Endocr Connect* 2017;6(8):557–65.
  37. Gill AJ, Lim G, Cheung VKY, Andrici J, Perry-Keene JL, Paik J, et al. Parafibromin-deficient (HPT-JT Type, CDC73 Mutated) Parathyroid Tumors Demonstrate Distinctive Morphologic Features. *Am J Surg Pathol* 2019;43(1):35–46.
  38. Iacobone M, Camozzi V, Mian C, Pennelli G, Pagetta C, Casal Ide E, et al. Long-Term Outcomes of Parathyroidectomy in Hyperparathyroidism-Jaw Tumor Syndrome: Analysis of Five Families with CDC73 Mutations. *World J Surg* 2020;44(2):508–16.
  39. du Preez H, Adams A, Richards P, Whitley S. Hyperparathyroidism jaw tumour syndrome: a pictorial review. *Insights Imaging* 2016;7(6):793–800.
  40. Chen Y, Hu DY, Wang TT, Zhang R, Dong Q, Xu ZX, et al. CDC73 gene mutations in sporadic ossifying fibroma of the jaws. *Diagn Pathol* 2016;11(1):91.
  41. Rodrigo JP, Hernandez-Prera JC, Randolph GW, Zafereo ME, Hartl DM, Silver CE, et al. Parathyroid cancer: An update. *Cancer Treat Rev* 2020;86:102012.
  42. Salcuni AS, Cetani F, Guarnieri V, Nicastro V, Romagnoli E, de Martino D, et al. Parathyroid carcinoma. *Best Pract Res Clin Endocrinol Metab* 2018;32(6):877–89.

43. Sarquis MS, Silveira LG, Pimenta FJ, Dias EP, Teh BT, Friedman E, et al. Familial hyperparathyroidism: surgical outcome after 30 years of follow-up in three families with germline HRPT2 mutations. *Surgery* 2008;143(5):630-40.
44. Kutcher MR, Rigby MH, Bullock M, Trites J, Taylor SM, Hart RD. Hyperparathyroidism-jaw tumor syndrome. *Head Neck* 2013;35(6):E175-7.
45. Bradley KJ, Hobbs MR, Buley ID, Carpten JD, Cavaco BM, Fares JE, et al. Uterine tumours are a phenotypic manifestation of the hyperparathyroidism-jaw tumour syndrome. *J Intern Med* 2005;257(1):18-26.
46. Arfi A, Chabbert-Buffet N, Boudy AS, de Foucher T, Owen C, Bendifallah S, et al. Benign polypoid adenomyomatous endometrium associated with hpt-JT syndrome: a case report. *Gynecol Endocrinol Off J Int Soc Gynecol Endocrinol* 2020;36(1):30-2.
47. Vocke CD, Ricketts CJ, Ball MW, Schmidt LS, Metwalli AR, Middleton LA, et al. CDC73 Germline Mutation in a Family With Mixed Epithelial and Stromal Tumors. *Urology* 2019;124:91-7.