

## Review Article

# Impact of diabetes mellitus on maxillofacial complex and orthodontic treatment

Maria Bampiolaki<sup>1</sup>, Christos Zafeiris<sup>1</sup>, Aliki Rontogianni<sup>2</sup>, Apostolos I. Tsolakis<sup>2,3</sup>

<sup>1</sup>Laboratory of Research of the Musculoskeletal System, National and Kapodistrian University of Athens, KAT Hospital, Athens, Greece;

<sup>2</sup>Department of Orthodontics, School of Dentistry, National and Kapodistrian University of Athens, Athens, Greece;

<sup>3</sup>Department of Orthodontics, School of Dental Medicine, Case Western Reserve University, Cleveland, USA

### Abstract

Diabetes mellitus is one of the most common metabolic disorders, diagnosed in 3% to 4% of the population. Its main characteristic is hyperglycemia caused by the body's impaired insulin management. Two major types of diabetes mellitus exist. Type 1 is a complete lack of insulin secretion. Type 2 combines impedance to insulin action and inadequate compensatory insulin secretion. Although, most of the orthodontic patients under orthodontic treatment are young persons in good health condition, lately there has been a great rise in the number of adults seeking orthodontic treatment. Many adults suffer from systematic diseases, including diabetes mellitus. There are various oral manifestations of the disease and they are mainly detected to patients with either poorly controlled or completely uncontrolled diabetes. Moreover, diabetes mellitus seems to affect temporomandibular joint function and may cause bone alterations. Diabetes mellitus is a metabolic disorder which every single dentist encounters, hence it is essential, that he is able to recognize its signs, symptoms, diagnostic and therapeutic aspects and face the emergencies when they arise. The aim of this article is to present the way in which diabetes mellitus affects patient's orthodontic treatment.

**Keywords:** Bone alterations, Diabetes mellitus, Orthodontic treatment, Temporomandibular joint

### Introduction

Commonly, the majority of orthodontic patients are healthy young individuals, however the most recent data, show a constantly higher number of older adults seeking orthodontic treatment. As age increases, more systemic diseases prevail among orthodontic patients. Dentists' awareness of the symptoms of diabetes mellitus and its early signs particularly in teeth and oral cavity is therefore necessary in order to make the diagnosis. It is also indispensable for them to be aware of the consequences of diabetes on orthodontic treatment and the measures that should be taken during management of those patients. In this review, we focused on the impact of diabetes mellitus on orthodontic treatment<sup>1</sup>.

### Materials and methods

For this article, information was gathered from Google Scholar and Pub Med. The terms searched were the following: "diabetes mellitus and orthodontic treatment",

"diabetes effect on temporomandibular joint" and "diabetes mellitus effect on temporomandibular joint". Search without restrictions with only exclusion of non – English papers.

### Results

After searching the term "diabetes mellitus and orthodontic treatment" in Google Scholar, 11.900 results

*The authors have no conflict of interest.*

**Corresponding author:** Maria Bampiolaki, Laboratory of Research of the Musculoskeletal System, National and Kapodistrian University of Athens, KAT Hospital, Athenas 10, 14561, Kifisia, Athens, Attica, Greece

**E-mail:** mariampampiolaki@hotmail.com

**Edited by:** Konstantinos Stathopoulos

**Accepted 28 June 2021**

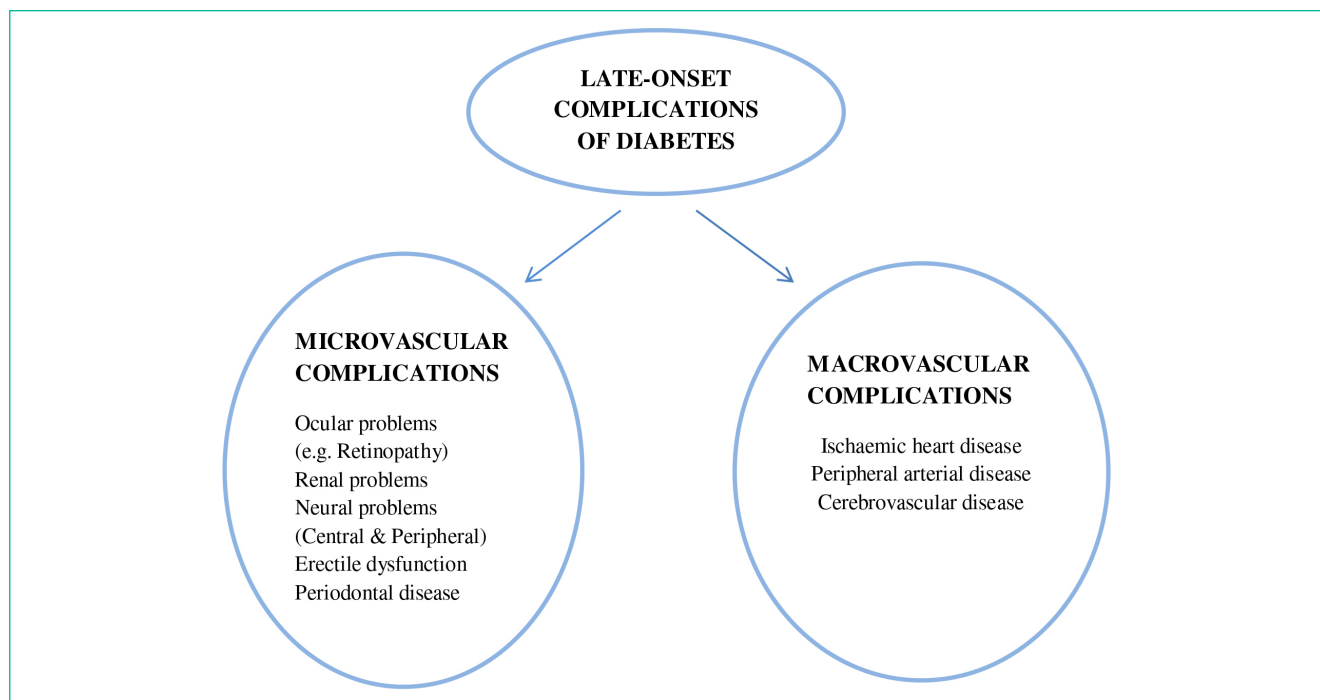


Figure 1. Late-onset complications of diabetes.

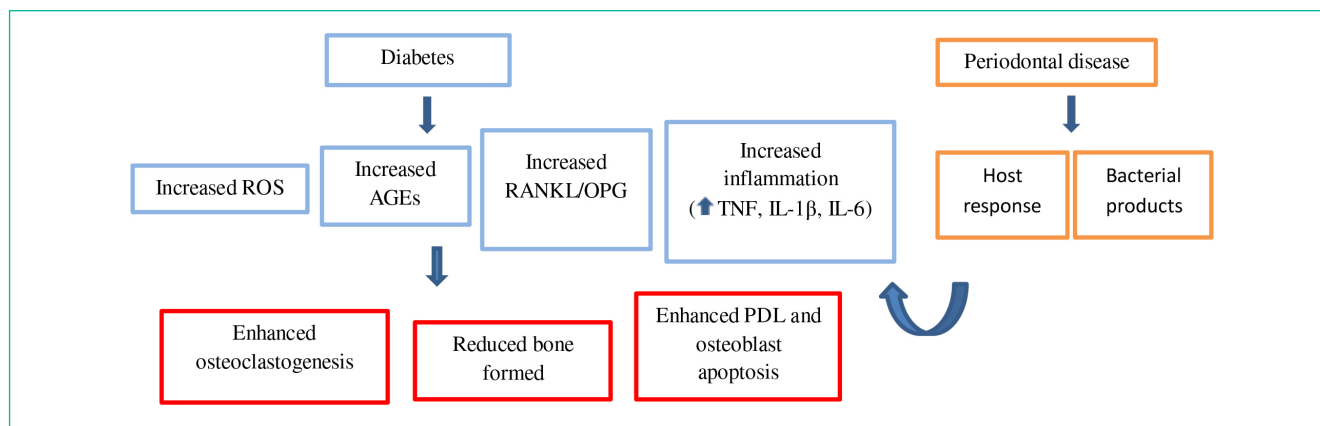
appeared. Forty seven (47) out of them were associating diabetes mellitus with orthodontic treatment. After searching the term “diabetes effect on temporomandibular joint”, 19.400 results appeared, and only five (5) of them referred to temporomandibular joint disorders related to diabetes mellitus. Finally, thirty four (34) results appeared after entering the term “diabetes mellitus and orthodontic treatment”, in PubMed, and only thirteen (13) of them were relating diabetes mellitus with orthodontic treatment. Also nine (9) items appeared after searching “diabetes mellitus effect on temporomandibular joint”, in PubMed. Sixty – one articles were found to be eligible and are included in this review.

### **General description and clinical features of diabetes mellitus**

Diabetes mellitus (DM) is a common and serious metabolic disorder, which is diagnosed in 3% to 4% of the population. Its main characteristic is the persistently high glucose levels in the blood. This situation also known as hyperglucemia, is the result of deficiencies in insulin secretion, insulin action, or both. Two main types of DM exist. Type 1 or insulin-dependent or juvenile diabetes, is a complete deficiency in insulin secretion. Type 2 combines impedance to insulin action and inadequate compensatory insulin secretion<sup>2-4</sup>. Apart from diabetes type 1 and 2, there is one more diabetes type which appears exclusively during pregnancy, and is

called “gestational diabetes”. Women, who are prone to diabetes, may show diabetes mellitus when being pregnant due to physiological and hormonal changes that occur in the meantime<sup>5</sup>. The rest of the types, were until recently known, as secondary diabetes<sup>6</sup>. Diabetes appears in individuals of all ages but there is a greater frequency in the age of fifty years old. The incidence of diabetes increases with age and as the life expectancy of the population has been extended, the number of diabetic patients will mark an upward trend as well<sup>7</sup>. It is stated as well that type 1 diabetes accounts for 5% to 10% of diabetic patients and appears more frequently at 10 to 14 years of age<sup>2,8</sup>. Also the incidence of type 1 diabetes shows great variation among racial groups and countries while it appears with the same frequency in both sexes<sup>9,10</sup>. Type 2 DM, is the most common type and affects 90-95% of diabetic population<sup>3</sup>.

Marked hyperglycemia appears with a variety of symptoms such as polydipsia, polyuria, polyphagia, general fatigue, weight loss and susceptibility to infections<sup>11-14</sup>. Also chronic hyperglycemia is associated with failure, dysfunction and long-term damage of various organs. Long-term complications of diabetes include ocular damage, kidney damage, autonomic and peripheral neuropathy and heart disease<sup>15,16</sup>, as well as gastrointestinal, genitourinary symptoms and sexual dysfunction<sup>12</sup> (Figure 1). Also, bone is adversely affected by the disease. In detail, being a dynamic organ, bone undergoes continuous remodeling to maintain its quantity and quality. As a result, the diabetic



**Figure 2.** Potential mechanism of diabetes-related alveolar bone loss in periodontal disease.

patient may show lower bone-mineral density, osteoporosis, osteopenia, Charcot's disease, and diffuse idiopathic skeletal hyperostosis. Furthermore, diabetic patients are in high risk of developing jaw osteonecrosis, associated with pharmaceutical treatment<sup>17</sup>. Finally, retarded growth in children has also been referred in cases of uncontrolled juvenile DM (JDM)<sup>18,19</sup>.

Common oral symptoms of diabetes include mouth dryness and burning (xerostomia), oral acetone smell in cases of poorly controlled diabetes, brittle teeth, dental caries, oral candida, mouth ulcerations, altered taste sensation, delayed healing of accidentally injured mucous membranes, and recurrent frequent infections<sup>1,20,21</sup>. Diabetes mellitus is also a predisposition for oral mucosal disturbances, for example angular cheilitis, geographic tongue, median rhomboid glossitis and pseudomembranous glossitis. It also predisposes to burning mouth syndrome, lichenoid reactions or glossodynia<sup>22-24</sup>. In addition, an increased tendency to develop gingivitis as well as periodontitis is observed towards diabetic patients<sup>15,16</sup>. Furthermore periodontitis is also considered to be the sixth complication of diabetes<sup>25</sup>.

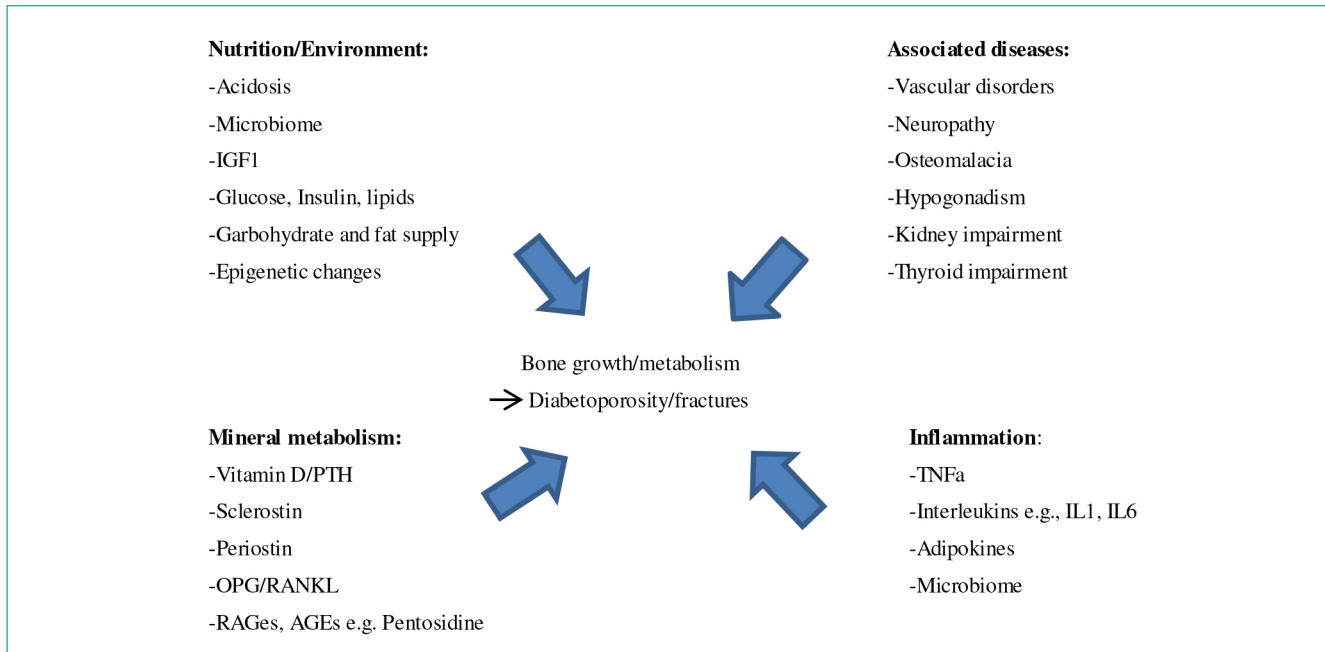
### **Orthodontic treatment in diabetic patient**

During orthodontic treatment it is preferable to schedule morning sessions and avoid long duration appointments (longer than 1½ hours). Also, it is necessary for the patient to have both usual meal and the scheduled medication. In this way a potential hypoglycemic reaction could be avoided. For this reason good medical control is prerequisite for any orthodontic treatment to diabetic patients (HbA1c 9%). Orthodontic treatment must not be an option for patients with uncontrolled diabetes. Overall there is no dental procedure that cannot be performed in patients with diabetes under good medical control and in fact no special precautions are necessary unless complications of the disease are present<sup>2</sup>. There are dental diseases that can be harmful for

the control of diabetes. Periodontitis is such an example, as it significantly increases blood glucose levels and their fluctuations<sup>1</sup> (Figure 2). Moreover, several epidemiologic and other surveys have described the bidirectional interrelationship between diabetes and periodontal disease. Periodontal tissue destruction may lead to tooth migration resulting in incorrect alignment in the dental arches<sup>1</sup>. Due to the increased tension for periodontal breakdown in diabetic patients and more specifically in poor controlled or uncontrolled diabetic patients, it is concluded that diabetic patients should be treated as periodontal patients<sup>26,27</sup>.

Both fixed and removable appliances are preferred for treatment. It is essential though, to highlight the importance of maintenance of good oral hygiene, exceptionally when it comes to fixed appliances. In detail, tooth decay and periodontal breakdown are expected to a greater extent. Candida infections are also a frequent phenomenon and in case they arise, glucose levels should be controlled in order to prevent deterioration of the disease<sup>2,28,29</sup>. Diabetes-related microangiopathy, is another significant issue that may sometimes shows up in the periapical vascular supply. This phenomenon can lead to odontalgia of no apparent reason, percussion sensitivity, pulp inflammation and loss of vitality in sound teeth. Particularly in orthodontic cases where great forces are required for tooth movement over a significant distance, the orthodontist should often check the vitality of the teeth involved. In general, mild forces should be applied on teeth, whereas overload should be avoided.

Antibiotic prophylaxis is necessary during certain orthodontic interventions. This is because diabetic patients' immune system is often compromised. More specifically, in procedures such as separator placement, orthodontic band placement, or screw insertion, danger of oral infection is greater. Hence prophylactic antibiotics are required before these procedures<sup>26,27</sup>.



**Figure 3.** Potential factors influencing diabetoporosity and related bone fracture risk.

### **Emergencies during orthodontic treatment in diabetic patients**

Orthodontists should always be aware and prepared for emergencies during orthodontic treatment in diabetic patients. The most dangerous among them, according to Almadih et al. is hypoglycemia<sup>1</sup>. Hypoglycemia occurs when serum blood glucose level drops below 50 mg/dl<sup>30</sup>. When patients develop hypoglycemia, they go through two stages; the neurogenic (or adrenergic) stage followed by the neuroglycopenic stage. During the adrenergic stage, there is a considerable activation of sympatho-adrenal systems which leads to shivering, cold sweating, tremors, and tachycardia. In case the diagnosis of this stage is missed, patients develop neuroglycopenic symptoms including dizziness, blurred vision, confusion, generalized weakness, and even coma and death<sup>30,31</sup>.

Dentists as well as orthodontists should be well-trained to early identify and manage hypoglycemia<sup>30,31</sup>. In all dental clinics there should be a protocol based treatment of hypoglycemia regarding conscious and unconscious patients. Snack foods, oral glucose gels or tablets should be dispensable for such emergencies, especially when minor surgical procedures are performed. Especially in children or adults who are not co-operating, glucose gels are very helpful, because glucose absorption starts as soon as it comes in touch with a mucosal surface<sup>32</sup>. As soon as the symptoms of hypoglycemia are recognized, oral glucose is to be administered in a dose of 50 g. If the patient is

unconscious, intramuscular glucagon of 1 mg or intravenous dextrose should be immediately infused<sup>33</sup>. Moreover, another remedy is asking from patients under insulin treatment, to monitor their blood glucose levels at their own glucometers in the office<sup>32</sup>. Also, lengthy orthodontic appointments should be arranged in the morning<sup>8,34,35</sup>, and the orthodontist should confirm that the patient has consumed his/her breakfast before<sup>1</sup>, and that he/she has taken his medication as usual<sup>8,34,35</sup>. Taking into account the prementioned recommendations, the orthodontist may eschew a possible hypoglycemic reaction in the clinic<sup>35</sup>.

The risk of a hypoglycemic reaction is increased, in some categories of patients. Such patients are those who have renal or hepatic diseases. In addition, blood glucose should be checked in diaphoretic patients. Finally, it is suggested that blood glucose levels should be monitored before sedation or systemic anesthesia and every one hour if surgery is long lasting<sup>32</sup>.

### **Bone alterations in diabetic patients**

Orthodontic tooth movement is based on the balanced remodeling of alveolar bone, in response to a prolonged applied force to the tooth<sup>17,36</sup>. This is achieved by resorption of the alveolar bone on the compression side due to the osteoclasts' action and by formation of the new bone on the tension side by osteoblasts. A different rate of tooth movement may result from changes in the metabolic state that affect bone remodeling. Hence, response to orthodontic treatment may be totally different between

patients with diabetes and healthy patients regarding how the periodontium and the alveolar bone respond to therapy.

Metformin (1-(diaminomethylidene)-3,3-Dimethylguanidine) is an oral anti-hyperglycemia drug usually administered for the treatment of type 2 diabetes mellitus. Metformin monotherapy has been found to offer protective effects against diabetic complications. Vestergaard et al.<sup>37</sup> reported decreased risk of bone fractures in patients with type 2 diabetes under metformin medication<sup>37</sup>. Furthermore, it is stated that metformin differentiates osteoblasts. Also adipogenic differentiation in rat's cultured marrow mesenchymal stem cells is inhibited by metformin. This is achieved through inhibition of peroxisome proliferator-activated receptor gamma, a nuclear receptor that regulates lipid and glucose metabolism<sup>38</sup>. Another property of metformin is that it promotes trabecular bone formation. Responsible for this is the activation of activated mononucleotide protein kinase (AMPK) signaling in osteoblastic cells. This is a major intracellular pathway that senses energy starvation<sup>39</sup>. What was assumed is that osteogenesis by metformin may be created only in mice with diabetes, whereas it is not observed in healthy mice<sup>40</sup>.

Braga et al.<sup>36</sup> found out that there was increase in bone resorption and abnormal tooth movement in diabetic rats. In addition, the number of TRAP-positive osteoclasts as well as the expression of cathepsin K of osteoclasts were both found to be augmented in rats with diabetes under orthodontic tooth movement. In the same rats tooth movement was found to be greater. Alkaline phosphatase (ALP), a major marker of osteoblast activity, was found to be at lower levels by immunostaining. As it appeared, the activity of osteoblasts was clearly decreased by diabetes. Similarly, it has been shown that diabetes decreases bone formation due to decreased osteoblastic activity<sup>41-43</sup> (Figure 3).

Type 2 diabetes patients present decreased, normal and increased BMD values in comparison to non-diabetic patients. Most of the studies concerning diabetes type 1, show that even when the onset of diabetes follows peak bone mass, BMD values are shown decreased. Either completely or partially, insulin therapy reverses impairment of organs related to hyperglycemia. However, remarkable bone alterations have been reported, not only in diabetic patients, but also in young patients and those under intensive insulin medication<sup>44-52</sup>.

Following application of orthodontic forces on Wistar rats with diabetes, without medication, an important decrease in areas covered by osteoblasts was found. Also total erosive lesions were shown in rats with chronic diabetes subjected to orthodontic forces in compared to sound rats that were subjected to the same mechanical stimulus. Bone response of insulin-treated diabetic rats subjected to orthodontic forces had no difference from that shown in normal rats subjected to similar orthodontic forces<sup>53</sup>.

Changes in lacunar shape and decreased density

indicate that alveolar bone's osteocytes, respond early to hyperglycemia. Osteocytes are part of the mechanotransduction which fixes osteogenesis in tension areas. Hence, early changes of these cells caused by hyperglycemia, may be related to lower bone formation, shown in diabetic rats exposed to orthodontic forces<sup>53</sup>.

Sun et al.<sup>17</sup> suggest that in experimental tooth movement osteoclasts' number and activity were raised due to diabetes, leading to a greater tooth movement. However, administration of metformin resulted in lower number and activity of osteoclasts and ameliorated osteoblast action. It also improved the function of osteocytes in these diabetic animals, leading to normalization of tooth movement. These potentially bone-protecting effects of metformin may be relevant in clinical settings of orthodontic tooth movement in diabetic patients<sup>17</sup>.

Overall, besides orthodontic tooth movement, craniofacial morphology related to general growth and skeletal maturation is distinct in individuals with juvenile diabetes. Patients with diabetes show decreased both skeletal maturation and growth parameters when compared with normal individuals<sup>54</sup>.

### ***Diabetes impact on temporomandibular joint***

According to Collin et al., neuropathy is the most common complication in type 2 diabetes mellitus. Neuropathy affects more than half of patients with 10 years duration of the disease. However, the role of diabetic neuropathy in oral symptoms and diseases, is not known enough yet. Pain, dysesthesia, and loss of sensation are caused by peripheral neuropathy. Autonomic neuropathy may cause alterations at the salivary flow rate<sup>55-57</sup>.

Peripheral neuropathy is considered to be a risk factor for serious temporomandibular joint dysfunction. Teeth loss or temporomandibular joint dysfunction may be the end result of contribution of several contributing mechanisms. Loss of sensation in peripheral neuropathy can induce joint disorders and deformities such as Charcot's joint. Additionally, in cases of hyperesthesia or dysesthesia, daily oral hygiene may be neglected which may indirectly result in deterioration of teeth condition as a consequence of neuropathy. This is the reason why meticulous examination is necessary and cannot be skipped, in order to avoid mistaken tooth extractions due to unspecified pain. Collin et al. conclude that according to the result, being early indicators of neuropathy, tooth loss or TMJ dysfunction should be signals to the physician<sup>58</sup>.

Poorly controlled diabetic patients may show temporomandibular joint disorder as well as trigeminal pain, which may be associated with diabetic neuropathy. Usually, in these cases of diabetes, oral cavity examination is neglected during routine diabetes checkup, fact that opposes the recommendations by the American Diabetes Association and other professional societies. This may not be surprising though, as pain, bleeding, or other symptoms are often absent from oral conditions and diseases or even

no oral complaints are mentioned to the physicians at all<sup>59</sup>. Moreover, the syndrome of limited joint mobility, also known as cheiroarthropathy, stiff hand syndrome, diabetic stiff hand and diabetic contractures, is one more significant disorder contributing to musculoskeletal complaints of patients with diabetes<sup>60</sup>. Finally, flexibility of temporomandibular joint is limited in diabetic patients. Regular breaks for the patient are recommended during the dental process which requires prolonged immobility. In this way the orthodontist allows the patient to move his/her stiff joints. Nonetheless, currently, there are no published data suggesting that temporomandibular joint dysfunction prevails among patients with diabetes mellitus, therefore new studies need to be designed<sup>61</sup>.

## Conclusions

Over the last years, the orthodontist often faces patients with diabetes mellitus as the orthodontic treatment is addressed to a wide age range. Consequently, it is essential for the orthodontist to be able to identify oral manifestations of diabetes in orthodontic patients, prevent potential complications and face them. Deep knowledge of bone pathophysiology in diabetic conditions is imperative in order to achieve a functional and successful orthodontic result. Last but not least, an issue which is in need of further survey and study, is that concerning the function of temporomandibular joint which is impaired, thus making the orthodontic treatment more complicated.

## References

- Almadih A, Al-Zayer M, Dabel S, Alkhalaf A, Al Mayyad A, Bardisi W, et al. Orthodontic Treatment Consideration in Diabetic Patients. *J Clin Med Res* 2017;10(2):77-81.
- Bensch L, Braem M, Van Acker K, Willems G. Orthodontic treatment considerations in patients with diabetes mellitus. *Am J of Orthod and Dentofacial Orthop* 2003;123(1):74-78.
- Lalla RV, D'Ambrosio JA. Dental management considerations for the patient with diabetes mellitus. *Dentistry & Medicine* 1999;132.
- Classification and Diagnosis of Diabetes Mellitus and Other Categories of Glucose Intolerance. *Diabetes* 1979;28(12):1039-1057.
- Report of the Expert Committee on the Diagnosis and Classification of Diabetes Mellitus. *Diabetes Care*. 1997;20(7):1183-1197.
- Ellenberg, M, Rifkin, H. *Diabetes mellitus, theory and practice*. New York, Medical Examination Publishing Co, Inc 1983;3:310-311, 411-412.
- Amos AF, McCarty DJ, Zimmet P. The rising global burden of diabetes and its complications: estimates and projections to the year 2010. *Diabet Med* 1997;14(5):81-5.
- Burden D, Mullally B, Sandler J. Orthodontic treatment of patients with medical disorders. *Eur J Orthod* 2001;23(4):363-372.
- Green A, Gale E, Patterson C. Incidence of childhood-onset insulin-dependent diabetes mellitus: the Eurodiab Study. *Lancet* 1992;339:905-9.
- Karvonen M, Tuomilehto J, Libman I, LaPorte R. A review of the recent epidemiological data on the worldwide incidence of type 1 (insulin-dependent) diabetes mellitus. World Health Organization diamond project group. *Diabetologia* 1993;36:883-92.
- Pfeffer MA, Claggett B, Diaz R, Dickstein K, Gerstein HC, Kober LV et al. Lixisenatide in Patients with Type 2 Diabetes and Acute Coronary Syndrome. *N Engl J Med* 2015;373(23):2247-2257.
- American Diabetes A. Diagnosis and classification of diabetes mellitus. *Diabetes Care* 2014;37(1):81-90.
- Romesh Khardori GTG. Type 1 diabetes mellitus: practice essentials, background, pathophysiology.
- Little JW, Falace DA, Miller CS, Rhodus NL. *Dental Management of the Medically Compromised Patient* 4<sup>th</sup> ed. St Louis: C. V. Mosby. p 349.
- Finney LS, Finney MO, Gonzalez-Campoy JM. What the mouth has to say about diabetes. *Diabetes* 1997;102:117-26.
- Loe H. Periodontal disease: the sixth complication of diabetes mellitus. *Diabetes Care* 1993;16:329-34.
- Sun J, Du J, Feng W, Lu B, Liu H, Guo J, et al. Histological evidence that metformin reverses the adverse effects of diabetes on orthodontic tooth movement in rats. *J Mol Histol* 2016;48(2):73-81.
- Sterky G. Growth pattern in juvenile diabetes. *Acta Paediatr* 1967;56:80-82.
- Chew FS. Radiologic manifestations in the musculoskeletal system of miscellaneous endocrine disorders. *Radiol Clin North Am* 1991;29:135-147.
- Kasper DL, Braunwald E, Fauci AS, Longo DL, Hauser SL. *Harrison's Principles of Internal Medicine*. United States of America: McGraw-Hill Companies 2005;16:2153, 2158, 2159.
- Newmon M, Takei HH, Carranza FA. *Carranza's Clinical Periodontology*. Pennsylvania: Saunders, Elsevier 2003;(9):208-210.
- Albrecht M, Banoczy J, Dinya E, Tamas G. Occurrence of oral leukoplakia and lichen planus in diabetes mellitus. *J Oral Pathol Med* 1992;21:364-6.
- Bergdahl J, Anneroth G. Burning mouth syndrome: literature review and model for research and management. *J Oral Pathol Med* 1993;22:433-8.
- Lamey P-J, Darwazeh AMG, Frier BM. Oral disorders associated with diabetes mellitus. *Diabetic Med* 1992;9:410-6.
- Li X, Zhang L, Wang N, Feng X, Bi L. Periodontal Ligament Remodeling and Alveolar Bone Resorption During Orthodontic Tooth Movement in Rats with Diabetes. *Diabetes Technol Ther* 2010;12(1).
- Rizvi S, Pattabiraman V, Pai S, Sabrish S. Diabetes mellitus, a dilemma in orthodontics. *J Orthod* 2014;2(3):113-117.
- Tong DC, Rothwell BR. Antibiotic prophylaxis in dentistry: a review and practice recommendations. *J Am Dent Assoc* 2000;131(3):366-374.
- Firkin D, Ferguson J. Diabetes mellitus and the dental patient. *NZ Dent J* 1985;81:7-11.
- Geza T, Rose L. Dental correlations for diabetes mellitus. In: Rose LF, Kaye D, editors. *Internal medicine for dentistry*. St Louis: C.V. Mosby; 1990;2:1153.
- Ohashi Y, Wolden ML, Hyllested-Winge J, Brod M. Diabetes management and daily functioning burden of non-severe hypoglycemia in Japanese people treated with insulin. *J Diabetes Investig* 2017;8(6):776-782.
- Sequist ER, Anderson J, Childs B, Cryer P, Dagogo-Jack S, Fish L, et al. Hypoglycemia and diabetes: a report of a workgroup of the American Diabetes Association and the Endocrine Society. *Diabetes Care* 2013;36(5):1384-1395.
- Kidambi S, Patel SB. Diabetes mellitus Considerations for dentistry. *The Journal of the American Dental Association*, 2008;139:8-18.
- American Diabetes A. 13. Diabetes care in the hospital. *Diabetes Care* 2016;39(1):99-104.
- Chauhan N, Parikh T, Patel S, Shah A, Pandya P, Shah K. Diabetes mellitus, a myth in orthodontics? *International Journal of Preventive and Clinical Dental Research* 2018;5(3):24-28.

35. Maia LGM, Monini AC, Jacob HB, Gandini Jr LG. Maxillary ulceration resulting from using a rapid maxillary expander in a diabetic patient. *The Angle Orthodontist* 2011;81(3):546-550.
36. Braga SMG, de Albuquerque Taddei SR, Andrade I Jr, Queiroz-Junior CM, Garlet GP, Repeke CE, et al. Effect of diabetes on orthodontic tooth movement in a mouse model. *Eur J Oral Sci* 2011;119:7-14.
37. Vestergaard P, Rejnmark L, Mosekilde L. Relative fracture risk in patients with diabetes mellitus, and the impact of insulin and oral antidiabetic medication on relative fracture risk. *Diabetologia* 2005;48:1292-1299.
38. Gao Y, Xue J, Li X, Jia Y, Hu J. Metformin regulates osteoblast and adipocyte differentiation of rat mesenchymal stem cells. *J Pharm Pharmacol* 2008;60:1695-1700.
39. Shah M, Kola B, Bataveljic A, Arnett TR, Viollet B, Saxon L, et al. AMP-activated protein kinase (AMPK) activation regulates in vitro bone formation and bone mass. *Bone* 2010;47:309-319.
40. Jeyabalan J, Viollet B, Smitham P, Ellis SA, Zaman G, Bardin C, et al. The antidiabetic drug metformin does not affect bone mass in vivo or fracture healing. *Osteoporos Int* 2013;24:2659-2670.
41. Hie M, Shimono M, Fujii K, Tsukamoto I. Increased cathepsin K and tartrate-resistant acid phosphatase expression in bone of streptozotocin-induced diabetic rats. *Bone* 2007;41:1045-1050.
42. Botolin S, Faugere MC, Malluche H, Orth M, Meyer R, McCabe LR. Increased bone adiposity and peroxisomal proliferator-activate receptor-gamma2 expression in type I diabetic mice. *Endocrinology* 2005;146:3622-3631.
43. He H, Liu R, Desta T, Leone C, Gerstenfeld LC, Graves DT. Diabetes causes decreased osteoclastogenesis, reduced bone formation, and enhanced apoptosis of osteoblastic cells in bacteria stimulated bone loss. *Endocrinology* 2004;145:447-452.
44. Auwerx J, Dequeker J, Bouillon R, Geusens P, Nijs J. Mineral metabolism and bone mass at peripheral and axial skeleton in diabetes mellitus. *Diabetes* 1998;37:8-12.
45. Mu~noz-Torres M, Jodar E, Escobar-Jimenez F, Lopez-Ibarra PJ, Luna JD. Bone mineral density measured by dual energy x-ray absorptiometry in Spanish patients with insulin-dependent diabetes mellitus. *Calcif Tissue Int* 1996;58:316-9.
46. Tuominen JT, Impivaara O, Puukka P, Ronnema T. Bone mineral density in patients with type 1 and type 2 diabetes. *Diabetes Care* 1999;22:1196-200.
47. Reinwald S, Peterson RG, Allen MR, Burr DB. Skeletal changes associated with the onset of type 2 diabetes in the ZDF and ZDSD rodent models. *Am J Physiol Endocrinol Metab* 2009;296:E765-74.
48. Wakasugi M, Wakao R, Tawata M, Gan N, Koizumi K, Onaya T. Bone mineral density by dual energy x-ray absorptiometry in patients with non-insulin-dependent diabetes mellitus. *Bone* 1993;14:29-33.
49. Barrett-Connor E, Kritiz-Silverstein D. Does hyperinsulinemia preserve bone? *Diabetes Care* 1996;19:1388-92.
50. Stolk RP, van Daele PL, Pols HA, et al. Hyperinsulinemia and bone mineral density in an elderly population: the Rotterdam study. *Bone* 1996;18:545-9.
51. Guarneri MP, Weber G, Gallia P, Chiumello G. Effect of insulin treatment on osteocalcin levels in diabetic children and adolescents. *J Endocrinol Invest* 1993;16:505-9.
52. Hofbauer LC, Brueck CC, Singh SK, Dobnig H. Osteoporosis in patients with diabetes mellitus. *J Bone Miner Res* 2007;22:1317-28.
53. Villarino ME, Lewicki M, Ubios AM. Bone response to orthodontic forces in diabetic Wistar rats. *Am J Orthod Dentofacial Orthop* 2011;139(4):76-82.
54. El-Bialy T, Aboul-Azm SF, El-Sakhawy M. Study of craniofacial morphology and skeletal maturation in juvenile diabetics (Type I). *Am J Orthod Dentofacial Orthop* 2000;118(2):189-195.
55. Töyry JP, Niskanen LK, Mäntysaari MJ, Länsimies EA, Uusitupa MJ. Occurrence, predictors, and clinical significance of autonomic neuropathy in NIDDM. Ten-year follow-up from the diagnosis. *Diabetes* 1996;45:308-15.
56. Partanen J, Niskanen L, Lehtinen J, Mervaala E, Siitonen O, Uusitupa M. Natural history of peripheral neuropathy in patients with non-insulin-dependent diabetes mellitus. *N Engl J Med* 1995;333:89-94.
57. Newrick PG, Bowman C, Green D, O'Brien IAD, Porter SR, Scully C, et al. Parotid salivary secretion in diabetic autonomic neuropathy. *J Diabetic Compl* 1991;5:35-7.
58. Collin H-L, Niskanen L, Uusitupa M, Töyry J, Collin P, Koivisto A-M, et al. Oral symptoms and signs in elderly patients with type 2 diabetes mellitus. *Oral Surg Oral Med Oral Pathol Oral Radiol Endod* 2000;90(3):299-305.
59. Borgnakke WS, Anderson PF, Shannon C, Jivanescu A. Is There a Relationship Between Oral Health and Diabetic Neuropathy? *Curr Diab Rep* 2015;15(11).
60. Kapoor A, Sibbitt WL. Contractures in Diabetes Mellitus: The Syndrome of Limited Joint Mobility. *Semin Arthritis Rheum* 1989;18(3):168-180.
61. Arap A, Siqueira SRDT, Silva CB, Teixeira MJ, Siqueira JTT. Trigeminal pain and quantitative sensory testing in painful peripheral diabetic neuropathy. *Arch Oral Biol* 2010;55(7):486-493.