

Case Report

A new COL1A1 mutation in a Greek patient with osteogenesis imperfecta: Response to a low-dose protocol of zoledronic acid and two-year follow-up

Michail Sarantis¹, Panagoula Kollia², Stavroula Samara², Helen Athanasopoulou³, Yolanda Gyftodimou⁴, Dimitra Lianou⁵, Evdoxia Mpourazani⁵, Artemis Doulgeraki³

¹4th Department of Trauma and Orthopaedics, KAT Hospital, Athens, Greece; ²Department of Genetics & Biotechnology, Faculty of Biology, National and Kapodistrian University of Athens, Athens, Greece; ³Department of Bone and Mineral Metabolism, Institute of Child Health, Athens, Greece; ⁴Department of Clinical Genetics, Institute of Child Health, Athens, Greece; ⁵1st Department of Pediatrics, "Aghia Sophia" Children's Hospital, Athens, Greece

Abstract

Osteogenesis Imperfecta is a severe metabolic bone disorder, mainly caused by mutations of COL1A1 and COL1A2 genes that encode type I procollagen. We report a case of a 7-year-old boy with OI phenotype (recurrent, low-energy fractures, blue sclerae), whose DNA analysis revealed a new mutation of the COL1A1 gene. Herein, his two-year follow-up and his response to current treatment is described (low-dose protocol of zoledronic acid). Also, an insight is given on his metabolic bone profile, unfolding the biochemical response of bone turnover to this bisphosphonate.

Keywords: Osteogenesis imperfecta, Collagen, ZoledronicX acid, Mutation

Introduction

Osteogenesis Imperfecta (OI) is an inherited disorder with marked clinical and genetic heterogeneity, that affects bone and connective tissue. Its main feature is low bone mass and strength, leading to bone fragility and deformities¹. It is also frequently associated with muscle hypotonia, joint hypermobility, short stature, valvular heart disease, premature hearing loss, dentinogenesis imperfecta, easy bruising and blue sclerae. It is mostly caused by mutations in one of the two genes encoding type 1 procollagen (COL1A1 and COL1A2), resulting in qualitative (i.e. abnormal structure) and quantitative defects (i.e. decreased production) of collagen type 1. To date, seventeen genes have been implicated in the pathogenesis of this disease².

Collagen type 1 is the main structural protein of bone, tendons, ligaments, skin, dentin, and sclerae. It is a helical protein composed of three polypeptide chains, with a distinct three-dimensional structure^{1,3}. The presence of glycine in every third position of a collagen chain is a prerequisite for the correct folding of the three chains into a collagen triple helix⁴. Therefore, a mutation that changes this pattern can lead to OI, and it can be either inherited (autosomal dominant

or recessive) or de novo. We present a 7-year-old boy with a new mutation of COL1A1 gene and his clinical and biochemical response to intravenous zoledronic acid.

First presentation and baseline investigations

The patient, a seven year-old boy, first presented to the Department of Bone and Mineral Metabolism (Institute of Child Health, Athens, Greece) with a history of four, low energy fractures of long bones in a year (two of the left tibia, one of the left fibula and one of the distal phalanx of the right thumb) and blue sclerae (Figure 1). He had no other medical history of note and was on no medications.

The authors have no conflict of interest.

Corresponding author: Michail Sarantis, MD, 4th Department of Trauma and Orthopaedics, KAT Hospital, Nikis 2, 14561, Kifissia, Athens, Greece

E-mail: sarantismichalis@gmail.com

Edited by: Konstantinos Stathopoulos

Accepted 16 July 2018

Diagnostic tests	Result	Two-year follow up
Lateral Spine X-ray	Osteopenia; no fractures	Not Available
Eye examination	Normal	Normal
Audiogram	Normal	Normal
ECC/Cardiac ECHO	Normal	Normal
Dental review	Normal	Normal
Renal ultrasound	Normal	Normal
Parental DXA	Normal	-
Orthopaedic review	No deformities or scoliosis	Normal
DNA test for COL1A1, COL1A2	Heterozygosity of the c.2.578 G>T→Gly86O Stop mutation of COL1A1	New mutation, not found in mother (father declined testing)
DXA/bone markers/vitD	See table 2	See table 2

Table 1. Osteogenesis imperfecta diagnostic work up at presentation and follow up.

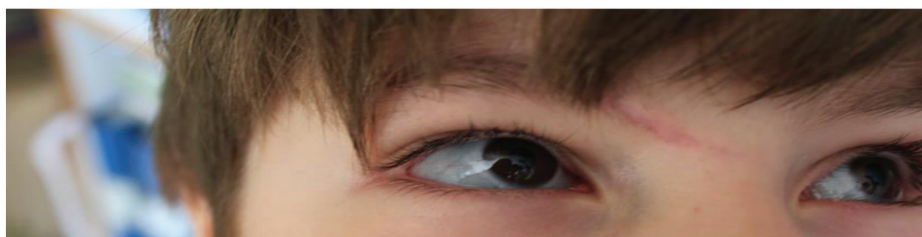

Figure 1. Characteristic blue sclerae of OI; post-traumatic laceration between the eyebrows.

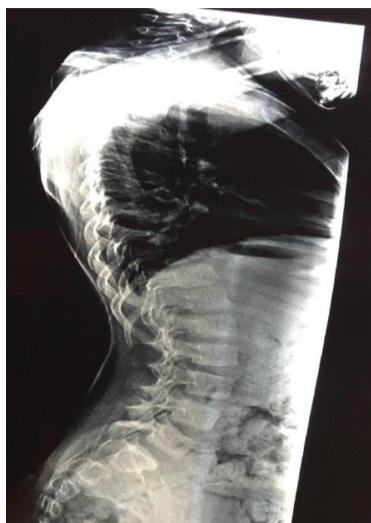

Figure 2. Baseline X-ray of the spine.

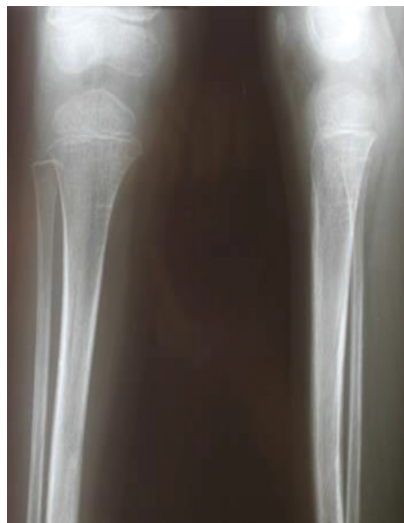

Figure 3. Thin, osteopenic long bones.

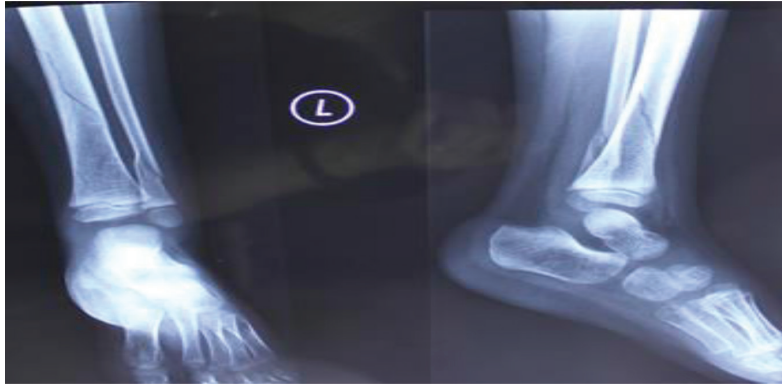


Figure 4. Fractures of the left tibia and fibula.

His dietary calcium intake was satisfactory, and he was exercising regularly.

In retrospect, his antenatal and perinatal history were unremarkable; his fetal growth, movements and anomaly scan were normal. He was born in good condition by Caesarian section, for failure to progress.

His parents are both Greek and non-consanguineous, with no family history of early osteoporosis, deafness, valvular heart disease or hernias. The patient has a step-sister who is now nineteen years old and healthy.

His physical examination was normal, with the exception of flexible joints and the typical triangular face and blue sclerae seen in OI. His teeth were also normal. There were no bone deformities or scoliosis. His hearing, intelligence and mobility were unaffected.

The patient's clinical picture was compatible with possible OI type 1; therefore, he underwent a full diagnostic work up, which is illustrated in Table 1. Also, he had a baseline lateral X-ray of the spine, which was diffusely osteopenic, but with no compression fractures (Figure 2). His long bones were slender and osteopenic as well (Figures 3, 4). Parental DXA scans were requested and they were normal.

Finally, DNA tests were performed for the index patient and the mother, to confirm the clinical impression of OI (his father declined DNA testing).

Establishing the OI diagnosis with DNA analysis

Initially, DNA sample from the patient (peripheral blood) was obtained, with parental consent. Genomic DNA was extracted with standard techniques and sequenced for the known polymorphisms and mutations of COL1A1 and COL1A2 genes. We enhanced gene COL1A1 (exons 1-51) and gene COL1A2 (exons 17, 19, 31, 52) with PCR and then analyzed the nucleotide sequence. We identified our patient as a heterozygote for the mutation *c.2.578 G>T→Gly860Stop*

of COL1A1 gene. No mutation was found on exons 17, 19, 31, 52 of COL1A2 gene. The aforementioned mutation results in a substitution of the amino acid 860 by a stop codon (NM_000088.3). Due to the premature termination of the COL1A1 protein, a significant region of the triple helix is lost, as well as the C-terminal propeptide and the fibrillar collagen NC1 region. This mutation has never been described before, neither to patients nor to healthy population and, given the clinical picture, it is most likely pathogenic. Regarding the maternal DNA test, it did not reveal any abnormality of the aforementioned genes.

Biannual follow up and the decision to treat

Initially, a wait-and-see approach was adopted, due to the absence of vertebral fractures and a degree of doubt as to the force that caused some of the long bone fractures. However, in the forthcoming months, two new fractures occurred on the left tibia and one more on the right tibia, rising the fracture number to a total of seven in two years. Therefore, he was scheduled for six-monthly doses of intravenous zoledronic acid (IV ZOL: 0.025 mg/kg/6months, according to our current protocol).

Pre-infusion tests included complete blood count, basic bone profile (including 25(OH)D and PTH) and bone turnover markers. DXA was performed annually, with GE Lunar Prodigy encore, Paediatric edition. Table 2 shows the patient's bone mineral density and bone turnover profile over time. He has received four infusions of IV ZOL so far, with no adverse events, apart from fever during the first infusion. No hypocalcaemia or hypophosphataemia have been recorded. He did sustain two more fractures during treatment, but these were both of the left fifth metatarsal bone, during sports, therefore they were not considered osteoporotic and no change has been made to his treatment plan. Otherwise, his clinical condition is stable, with normal height velocity, no scoliosis or bone deformities, no comorbidities and with steady rise in BMD at both sites of

Parameter	Baseline (pre-treatment)	After 1 st infusion	After 2 nd infusion	Comments/Lab ref. ranges
Age (years)	5	6.5	7	Next DXA: to be arranged
Height (cm)	111	-	121	Ht velocity: 5 cm/year
BMD Z-score L1-L4	-3	-	-2.3	Increased by 24%
BMD Z-score TBLH	-2.3	-	-0.9	Increased by 60%
Bone width	<1 st centile	-	2nd centile	Relatively stable
BMC/LTM ratio	13 rd centile	-	28th centile	Increased by 55%
Osteocalcin (ng/ml)	15.3	24.4	22.8	8-19
PICP (ng/ml)	42	31	35.5	>113
bTRAP5b (ng/ml)	-	7.2	3.8	2.5-13.2
uCa/uCreat (mmol/mmol)	0.32	0.1	0.11	<0.7
uDPD/uCreat (mmol/mmol)	59	26	30	10-35
25(OH)D (ng/ml)	21.6	31.8	32.7	20-100
PTH (pg/ml)	25.16	27.48	-	15-60

Note: BMD: bone mineral density, TBLH: total body less head, BMC: bone mineral content, LTM: lean tissue mass, PICP: procollagen type I C-propeptide, bTRAP5b: bone tartrate-resistant acid phosphatase type 5b, DPD: deoxypyridinoline, PTH: parathormone. BMD Z-scores are automatically derived by the DXA device; reference ranges for bone markers are those of the local laboratory (Greek controls, age- and sex-matched).

Table 2. Two-year follow up of growth, bone mineral density and bone turnover markers under treatment (low-dose protocol for IV ZOL).

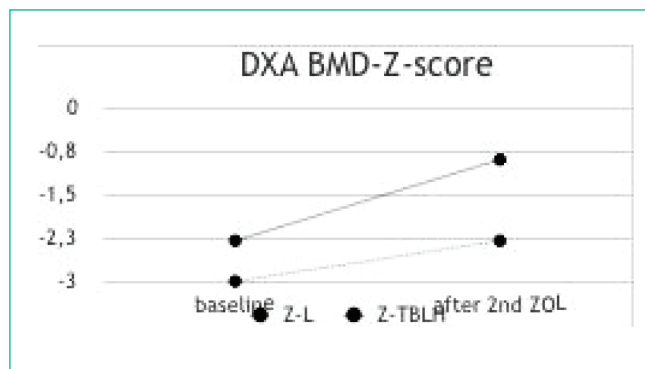


Figure 5. Trend of BMD of the spine and total body (less head) under treatment. Z-L: DXA BMD Z-score of lumbar spine (L1-L4), Z-TBLH: DXA BMD Z-score of total body (less head), ZOL: zoledronic acid.

measurement (Figure 5). Most importantly, IV ZOL seems to have a positive effect on the bone mineral content/lean tissue mass ratio (BMC/LTM, expressed in centiles), which serves as a surrogate for bone strength (reference range: 10th-90th centile for age and sex).

His vitamin D has always been normal, i.e. >20 ng/ml (>50 mmol/l), while on low dose cholecalciferol (400 iu/d). Finally, as a result of his antiresorptive therapy, his bone resorption

markers are reduced, compared to baseline, without complete suppression; this is important for the growing skeleton. With regards to PICP, this has always been low, probably because OI type I refers to quantitative defects of collagen, hence the milder phenotype, compared to other OI types, where collagen defects are qualitative (Figures 6, 7).

Discussion

Our patient is a heterozygote for the mutation c.2.578 G>T→Gly860Stop of COL1A1 gene that results in a substitution of the amino acid 860 glycine by a stop codon (NM_000088.3). A significant region of the triple helix (C-terminal propeptide and the fibrillary collagen NC1 region) is lost, due to the premature termination of the COL1A1 protein. The triple helical portion of each collagen chain contains 338 uninterrupted repeats of the triplet GXY (where G is glycine, X is often proline, and Y is often hydroxyproline). The presence of glycine, with the smallest side-chain in every third residue, is necessary for correct folding of the three chains into a collagen triple helix⁵. Such mutations often result in one null COL1A1 allele and decreased amount of procollagen type I, with normal structure. The synthesis of half the normal amount of functional pro- α 1 chains (due to the null allele) explain the mild clinical phenotype.

Bisphosphonates have been given to children with osteogenesis imperfecta for the last three decades. Zoledronic acid is becoming more and more popular globally.

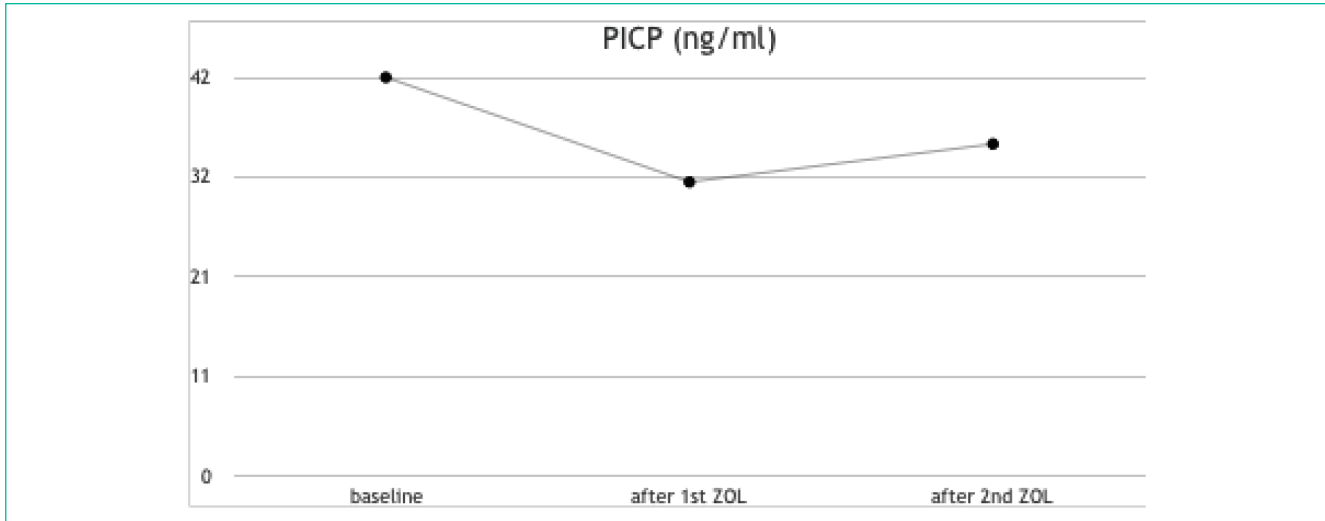


Figure 6. Low baseline PICP (marker of bone formation) and change of its levels over time under treatment.

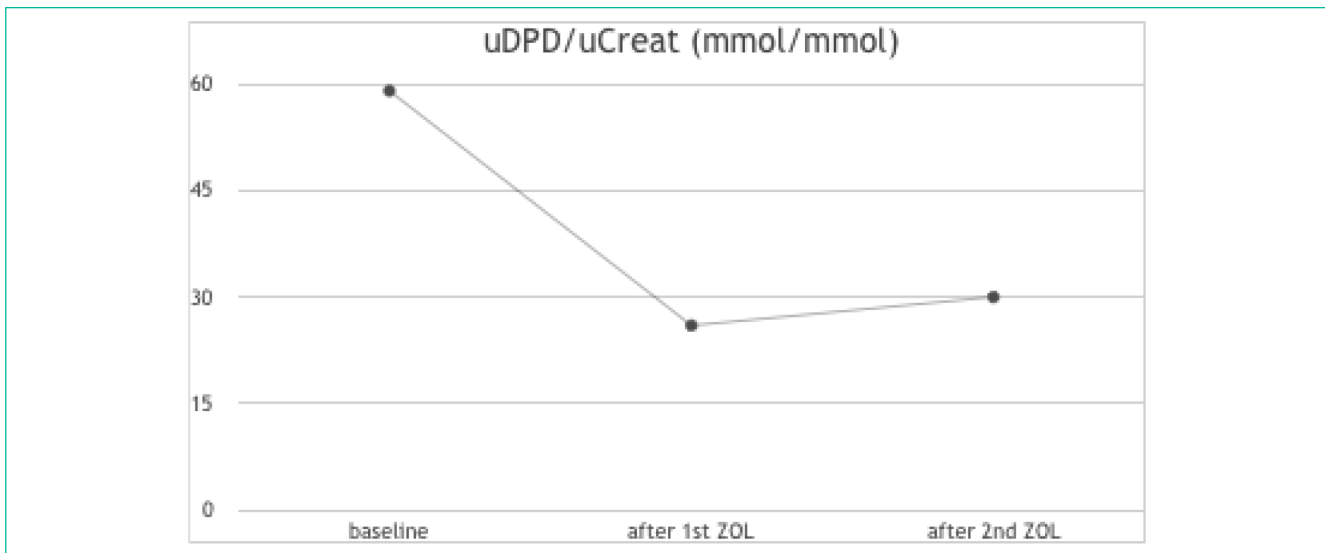


Figure 7. High baseline uDPD/uCreat (marker of bone resorption) and suppression over time.

It is a third generation bisphosphonate with high potency and very convenient to administrate, as it is given intravenously in 15 to 30 minutes and has a longer dosing interval. Current treatment protocols for the use of zoledronic acid in children with osteogenesis imperfecta recommend a dose range of 0.025-0.05 mg/kg every six months. The maximum single dose should be no more than 4 mg⁶.

The therapeutic approach in our institution, with the low-dose zoledronic acid infusion is mentioned in the figure below. This protocol is applied up to skeletal maturity

on an individualized basis, i.e. according to the clinical response (pain, fractures, deformities), BMD progress and metabolic bone profile, in order to avoid overtreatment, with osteosclerotic bone changes. The illustrated low-dose protocol (Figure 8) resulted in significant improvements of BMD at both sites of measurement in the index case.

During the two-year follow-up, our patient had normal growth and an improving BMD over time. More importantly, his fracture rate was reduced significantly, from 3.5 fractures/year to 1 fracture/year.

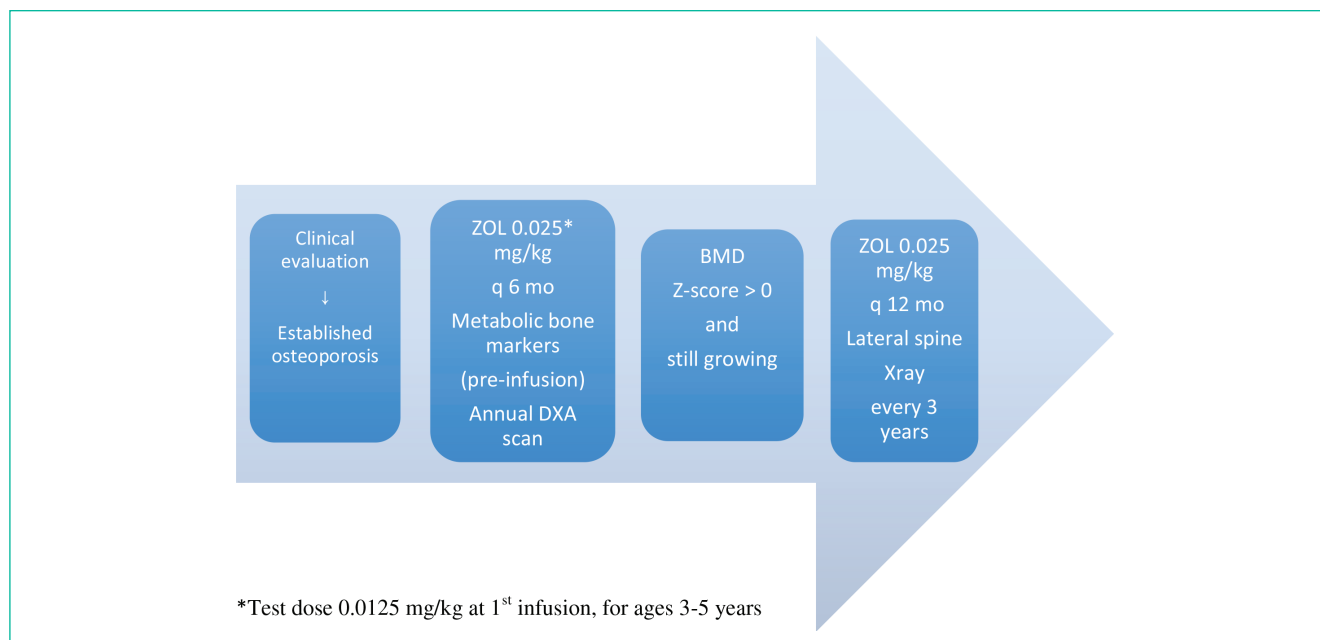


Figure 8. Low-dose protocol of intravenous zoledronic acid at a glance, for patients aged >3 years, under treatment.

His PICP remained low, as expected (collagen mutation, quantitative defect) and osteocalcin remained within reference ranges. His bone resorption markers were appropriately reduced and this was evident much earlier than his BMD improvement. Bisphosphonates are generally well tolerated by children with minor adverse effects, but require special attention for preventing the oversuppression of bone turnover. They are potent inhibitors of bone turnover, therefore, long term administration without proper follow up, may lead to “frozen bone”⁷. This term refers to a state of oversuppression of bone formation and resorption, which leads to an impaired healing of skeletal microfractures and susceptibility to further, atypical fractures. The safest degree of suppression of bone metabolism, to avoid suboptimal micro-damage repair is unknown⁸. As a matter of caution, we suggest that it is good practice to combine the clinical evaluation and interpretation of DXA scan with bone turnover markers, in line with osteoporosis treatment protocols for adults. However, there is no consensus on the ideal bone markers for paediatric populations, contrary to the adults, where P1NP and CTx are the markers of choice⁹. Also, although these indices are measured mainly for research purposes in children, they have not prevailed in everyday practice¹⁰. This calls for more studies on the subject, to ensure safer administration of bone-targeted therapy to children, whose skeleton is still growing.

Acknowledgements

The authors wish to thank the parents for consenting to the presentation of this case.

References

1. Forlino A, Cabral WA, Barnes AM, Marini JC. New perspectives on osteogenesis imperfecta. *Nat Rev Endocrinol* 2011; 7:540-557.
2. Forlino A, Marini JC. Osteogenesis imperfecta. *Lancet* 2016; 387:1657-71.
3. Bishop N. Characterising and treating osteogenesis imperfecta. *Early Hum Dev* 2010; 86:743-746.
4. Kadler KE, Holmes DF, Trotter JA, Chapman JA. Collagen fibril formation. *Biochem J* 1996; 311:1-11.
5. Gajko-Galicka A. Mutations in Type I collagen resulting in osteogenesis imperfecta in humans. *Acta Biochim Pol* 2002; 49(2):433-41.
6. Sobenna G. Short Term Safety of Zoledronic Acid in Young Patients with Bone Disorders: An extensive Institutional Experience. *J Clin Endocrinol Metab* 2015; 100(11):4163-71.
7. Matthew T. Drake. Bisphosphonates: Mechanism of Action and Role in Clinical Practice, *Mayo Clin Proc* 2008; 83(9):1032-1045.
8. Mashiba T, et al. Suppressed Bone Turnover by Bisphosphonates Increases Microdamage Accumulation and Reduces Some Biomechanical Properties in Dog Rib, *J Bone and Min Res* 2000; 15(4):613-620.
9. Lee J, Vasikaran S. Current recommendations for laboratory testing and use of bone turnover markers in management of osteoporosis. *Ann Lab Med* 2012; 32(2):105-12.
10. Tuchman S. Interpretation of Biomarkers of Bone Metabolism in Children: Impact of Growth Velocity and Body Size in Healthy Children and Chronic Disease. *J Pediatr* 153(4):484-490.